RhAPP

RHEUMATOLOGY ADVANCED PRACTICE PROVIDERS

RHAPP NATIONAL CONFERENCE

SEPTEMBER 8-10, 2022

Stranger Things: Recognizing the pulmonary mimics of ANCA-associated vasculitis

Naomi Amudala, MSN, RN
University of Pennsylvania
September 9, 2022

Disclosure Policy

All individuals in control of the content of continuing education activities provided by the Annenberg Center for Health Sciences at Eisenhower (ACHS) are required to disclose to the audience all relevant financial relationships related to the content of the presentation or enduring material. Full disclosure of all relevant financial relationships will be made in writing to the audience prior to the activity. All other staff at the Annenberg Center for Health Sciences at Eisenhower and RhAPP have no relationships to disclose.

Faculty Disclosures

- No disclosures

VASCULITIS MIMICS

Learning Objectives

1

Recognize the pulmonary manifestations of ANCA-associated vasculitis

2

Understand how to evaluate a patient who is suspected to have a vasculitis flare

3

Recognize mimics of pulmonary vasculitic manifestations

What Is ANCA-Associated Vasculitis (AAV)?

Variable Vessel Vasculitis

Behçet's Disease

Cogan's Syndrome

Single-Organ Vasculitis

CNS Vasculitis

Other Organs

Drug-Induced Vasculitis

Vasculitis in CTD

SLE, SSc, SjS, RA, etc.

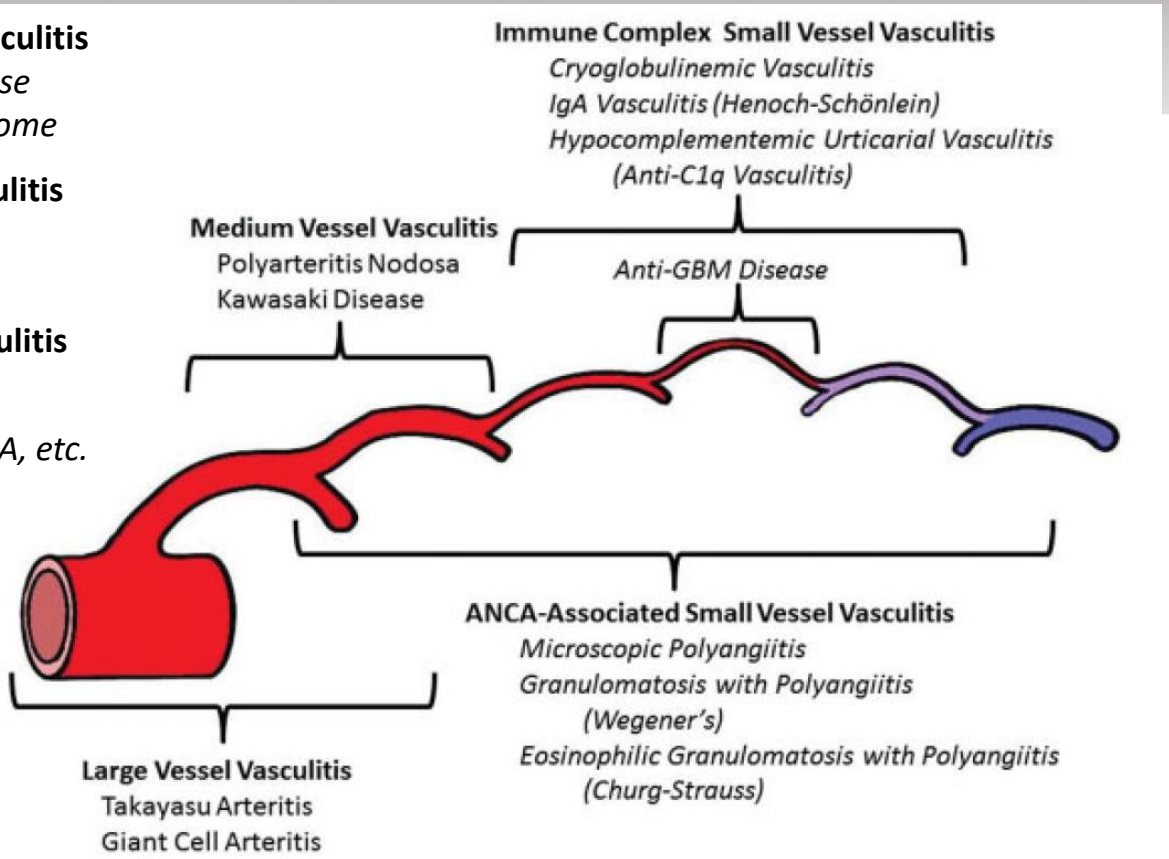

ARTHRITIS & RHEUMATISM
Vol. 65, No. 1, January 2013, pp 1–11

***Adapted from A&R* 2013**

ANCA-associated Vasculitis

Necrotizing inflammation of the small blood vessels

ANCA-associated vasculitis:

- Granulomatosis with Polyangiitis (GPA)
- Microscopic Polyangiitis (MPA)
- Eosinophilic granulomatosis with polyangiitis (EGPA)

Almost 90% of GPA/MPA patients will be ANCA positive

- GPA: PR3-ANCA positive
- MPA: MPO-ANCA positive
- EGPA: 30-50% MPO or PR3 ANCA positive (majority MPO positive)

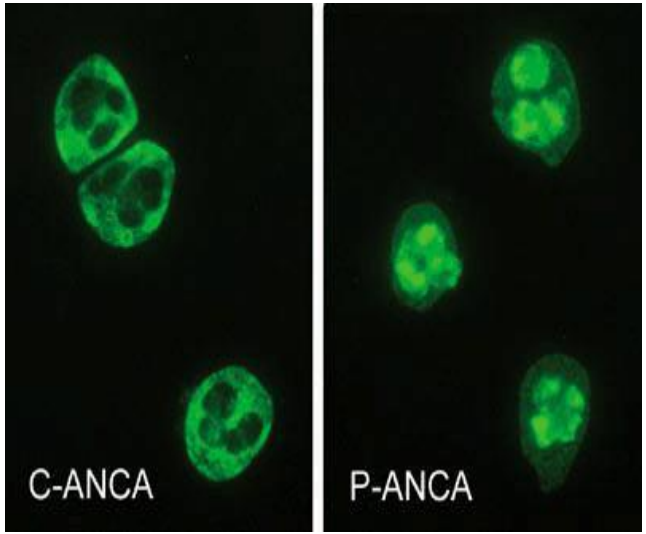

ANCA-Associated Vasculitis: Organ Involvement

General Symptoms

- Fever
- Weight Loss
- Fatigue
- Night sweats
- Malaise

Skin

- Palpable purpura
- Petechiae
- Urticaria
- Ulcers
- Livedo reticularis
- Nodules

Nervous System

- Neuropathy
- Mononeuritis multiplex
- CNS involvement rare

Ear and Nose

Nasal crusting
Rhinitis / sinusitis / epistaxis
Saddle nose deformity / nasal perforation
Hearing loss: Conductive or Sensioneural

Respiratory System

Pulmonary nodules
Diffuse alveolar hemorrhage
Subglottic stenosis

Renal system

Glomerulonephritis
Hematuria
Proteinuria
Rising creatinine

Heart

Pericarditis
Myocarditis
Coronary angiitis
Valvular disease
Congestive heart failure

Eye

Episcleritis
Scleritis

Joints

Arthralgia
Swelling
Arthritis

CASE PRESENTATION

24 year old F

Diagnosed at the age of 10 with GPA:

- Pauci-immune glomerulonephritis on renal biopsy
- Hematuria
- Fever
- Petechial rash
- Anemia
- Arthralgia
- Hearing loss
- Upper airway disease with saddle nose deformity
- C-ANCA positive with PR3 specificity on ELISA

Treatment course:

- IV cyclophosphamide
- Methotrexate
- Mycophenolate
- Rituximab
- As of 2017: maintained on rituximab every 6 months, methotrexate 25 mg weekly



Two week history

- Fevers up to 101 F
- Night sweats
- Slight cough

Covid in January, 2022

- Mild case
- Did not receive Paxlovid

Last received rituximab in Feb, 2022

Out-patient work-up

- Rapid COVID testing negative
- COVID PCR testing negative
- Blood cultures negative
- Urine cultures negative
- ANCA negative
- D-DIMER neg
- CD 19 count undetectable

Component	Value	Ref Range & Units	Status
UA Color	Straw	<=Dk Yel	Final
UA Appearance	Clear	<= Clear	Final
UA Glucose	Negative	Negative mg/dL	Final
UA Bilirubin	Negative	Negative mg/dL	Final
UA Ketones	Trace	Negative mg/dL	Final
UA Specific Gravity	<1.005	1.010 - 1.030	Final
UA Blood	Negative	Negative mg/dL	Final
UA pH	6.0	5.0 - 7.0	Final
UA Protein	Negative	Negative mg/dL	Final
UA Urobilinogen	Normal	mg/dL	Final
UA Nitrite	Negative	Negative	Final
UA Leukocyte Esterase	Negative	Negative Leu/ul	Final

BUN	2 - 23 mg/dL	11
Creatinine	0.60 - 1.30 mg/dL	0.71
Bun/Creatinine	5.0 - 28.0	15.5
Calcium	8.3 - 10.4 mg/dL	9.2
Alkaline Phosphatase	40 - 130 IU/L	120
Bilirubin Total	0.10 - 1.10 mg/dL	0.24
AST	8 - 48 IU/L	19
ALT	7 - 54 IU/L	10
Total Protein	5.9 - 8.2 g/dL	5.6
Albumin	3.0 - 5.0 g/dL	3.8
Globulin	1.6 - 4.0 g/dL	1.8
Albumin/Globulin Ratio	0.6 - 2.8	2.1
Fasting?		Unknown
Estimated GFR	>=60 mL/min/1.73 m2	>60

White Blood Cells	3.5 - 11.0 10^9/L	4.4
Red Blood Cells	4.00 - 5.20 10^12/L	4.41
Hemoglobin	12.0 - 16.0 g/dL	12.3
Hematocrit	36.0 - 46.0 %	37.7
MCV	80.0 - 100.0 fL	85.5
MCH	25.0 - 35.0 pg	27.9
MCHC	31.0 - 37.0 g/dL	32.6
RDW-SD	35.1 - 46.3 fL	43.6
RDW-CV	11.5 - 14.5 %	14.0
Platelet Count	140 - 444 10^9/L	221
MPV	6.5 - 12.3 fL	11.6
% Neutrophils	40.0 - 81.0 %	71.3
% Lymphocytes	18.0 - 42.0 %	21.8
% Monocytes	1.0 - 12.5 %	5.6
% Eosinophils	0.0 - 5.8 %	0.9
% Basophils	0.0 - 2.0 %	0.2
% Immature Granulocytes	0.0 - 1.0 %	0.2
Comment: Immature granulocytes are left-shifted granulocytes and do not equal blasts. They are composed of metamyelocytes, myelocytes, and p bone marrow stimuli. Occasionally, persistent increase in immature granulocytes may be part of myeloid neoplastic process. Correlation with clinical f blood with immature granulocytes >5% will be manually reviewed by lab personnel and/or pathologists.		
Absolute Neutrophils	1.8 - 8.0 10^9/L	3.2
Absolute Lymphocytes	1.0 - 4.8 10^9/L	1.0
Absolute Monocytes	0.0 - 0.9 10^9/L	0.2
Absolute Eosinophils	0.0 - 0.5 10^9/L	0.0
Absolute Basophils	0.0 - 0.2 10^9/L	0.0
Absolute Immature Granulocytes	0.00 - 0.03 10^9/L	0.01

C-Reactive Protein

	Ref Range & Units	Value
CRP	<=0.5 mg/dL	3.8

	Ref Range & Units	Value
Erythrocyte Sedimentation Rate	<=37 mm/hr	25

Physical Exam

- Well appearing
- Vital signs stable
- Heart and lung examinations unremarkable
- Sp02 98-100% on room air → 94% on ambulation

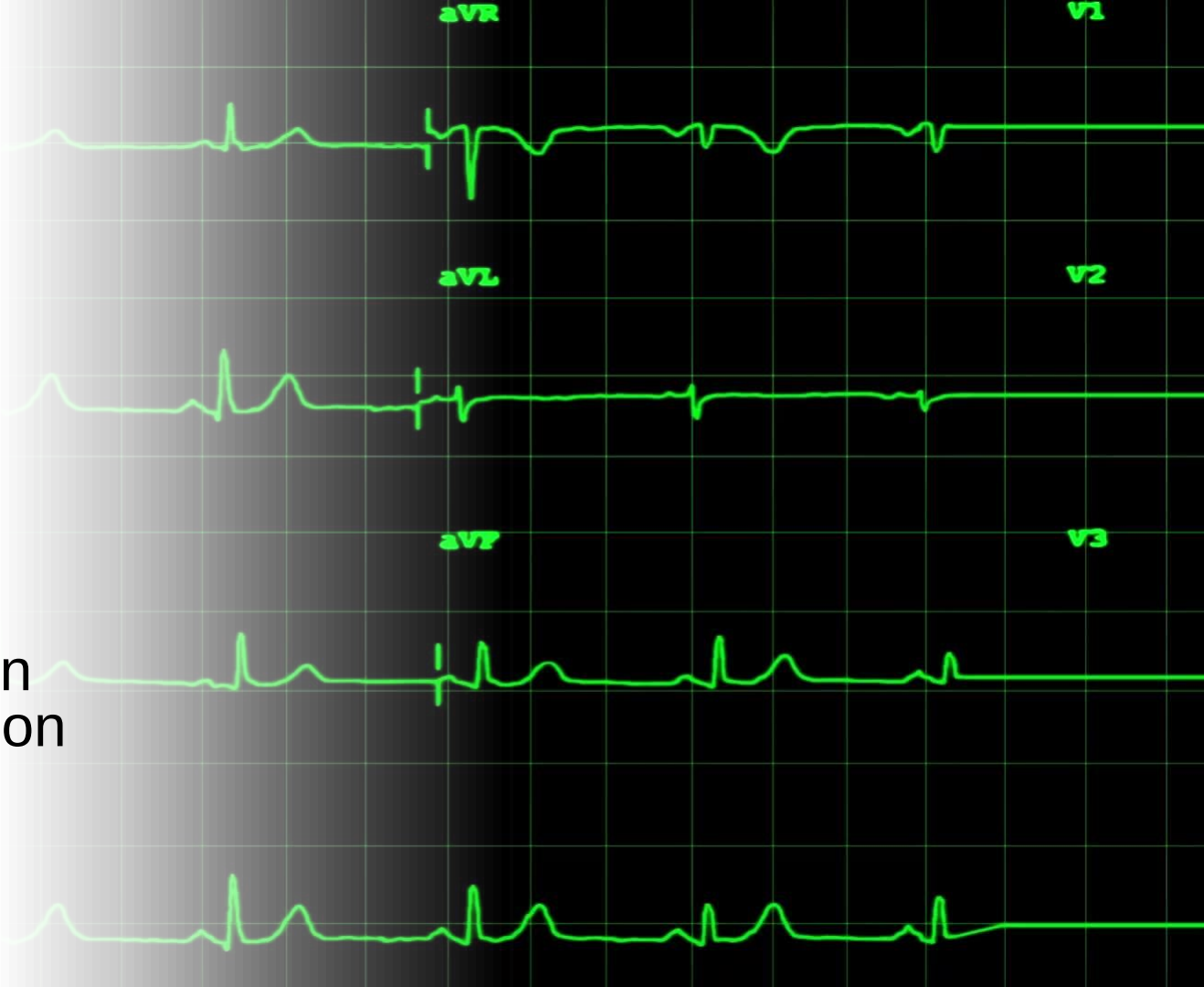

Chest x-ray 5/23/2022

EXAM: X-RAY CHEST 2 VIEWS

HISTORY: Chest tightness, productive cough for the past 1-2 weeks. Previous diagnosis of granulomatosis with polyangiitis.

TECHNIQUE: PA and lateral views of the chest.

COMPARISON: No prior imaging submitted.

FINDINGS:
Lungs/Airways: There is subtly coalescent accentuation of markings with slightly patchy character in the right infrahilar region, both anteriorly in the right middle lobe and in the right lower lobe posteriorly. There are a few accentuated markings in the left infrahilar region inferolaterally as well.

Mediastinum/Hila: Normal in contour.

Heart/Pericardium: Normal heart size and configuration.

Vasculature: No pulmonary vascular congestion.

Pleura: No effusions or thickening.

Bones: Unremarkable for age.

Other: Negative.

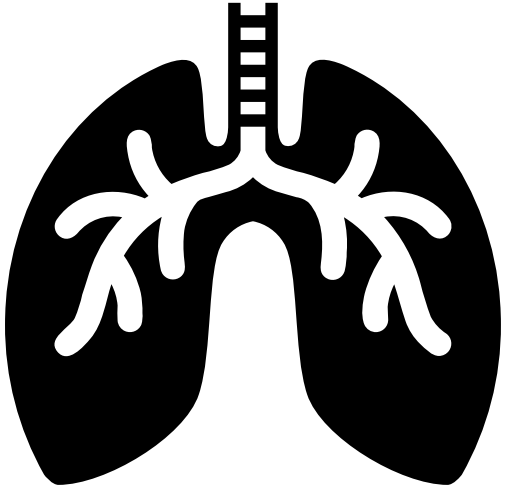

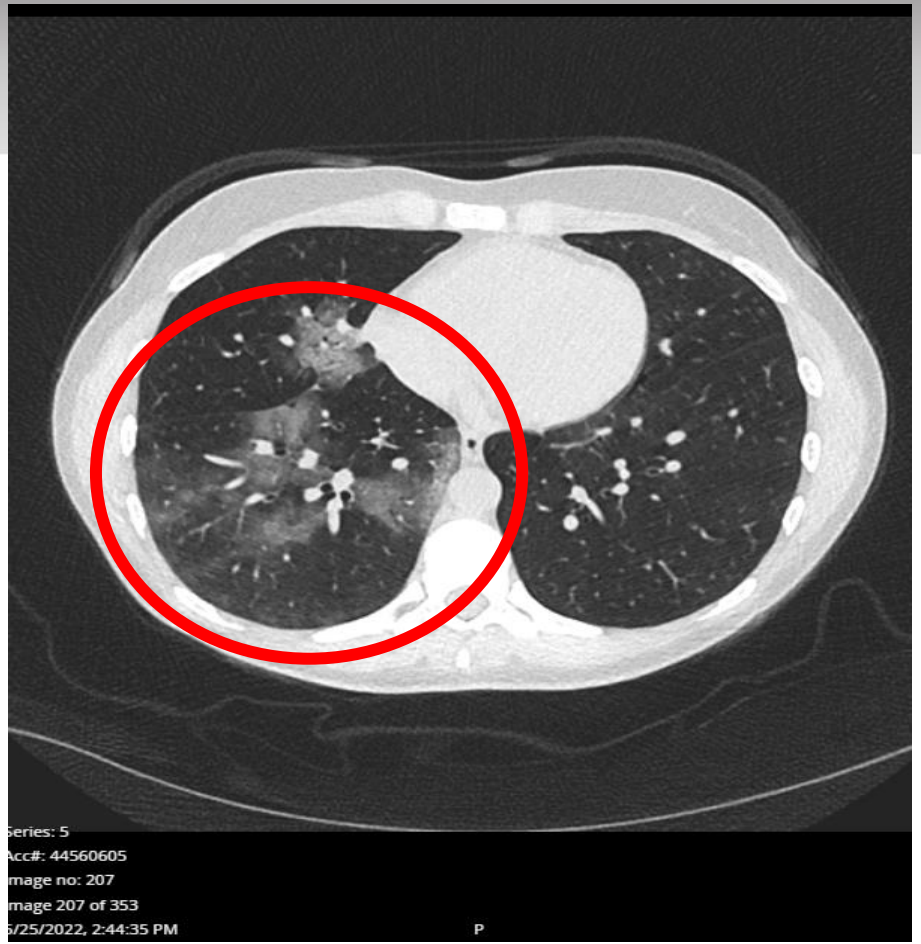
Series: 5
Acc#: 44560605
Image no: 207
Image 207 of 353
5/25/2022, 2:44:35 PM
P

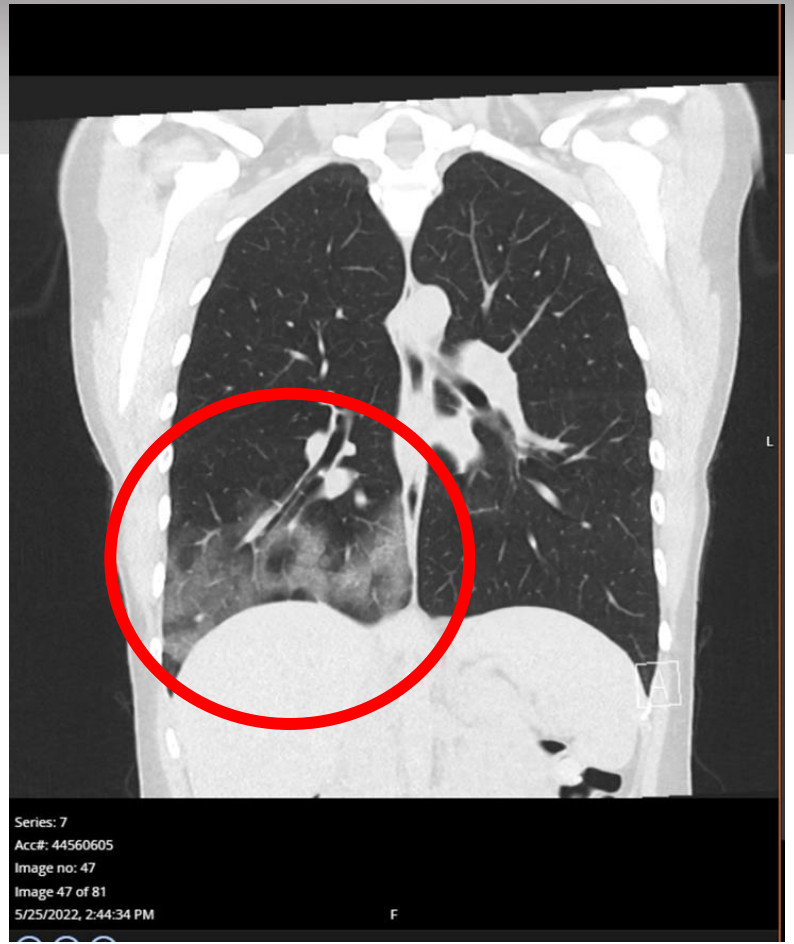
L
Series: 7
Acc#: 44560605
Image no: 47
Image 47 of 81
5/25/2022, 2:44:34 PM
F

Summary: History of GPA - maintained on rituximab plus methotrexate

Clue #1: Fevers plus night sweats on-going for 2 weeks

Clue #2: Slight oxygen desaturation on exertion

Clue #3: New ground glass opacities on chest CT scan

GPA flare?

Infection?

COVID?

Other?


NEW ROUTE TO
NORTH
GOV'T CTR
ATLANTIC
AVE
CALLAHAN
TUNNEL
BROAD ST
HIGH ST
STATE ST.
INDIA ST.
Financial
District
AQUARIUM
PARKING
P
BERKIE

PULMONARY MANIFESTATIONS OF ANCA-ASSOCIATED VASCULITIS

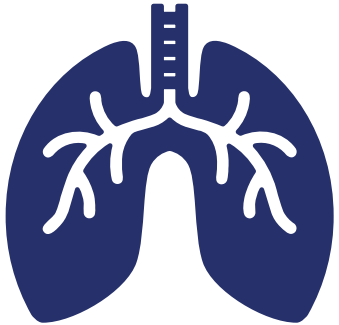

	GPA	MPA	EGPA
Nodules	50%[a]	7%[b]	14%[b]
Tracheobronchial involvement	15–55%[c]	50%[h]	Rare
DAH	22–30%[d]	25%[i]	4%[e]
ILD	23%[i]	45%[f]	39%[e]
Asthma	8%[b]	5%[b]	95–100%[g]

Sacoto G, Boukhlal S, Specks U, Flores-Suárez LF, Cornec D. Lung involvement in ANCA-associated vasculitis. Presse Med. 2020 Oct;49(3):104039. doi: 10.1016/j.lpm.2020.104039. Epub 2020 Jul 7. PMID: 32650042.

Common AAV pulmonary symptoms

- Dyspnea

- Cough

- Wheeze

Not so common AAV pulmonary symptoms

- Stridor

- Voice changes

- Hypoxemia

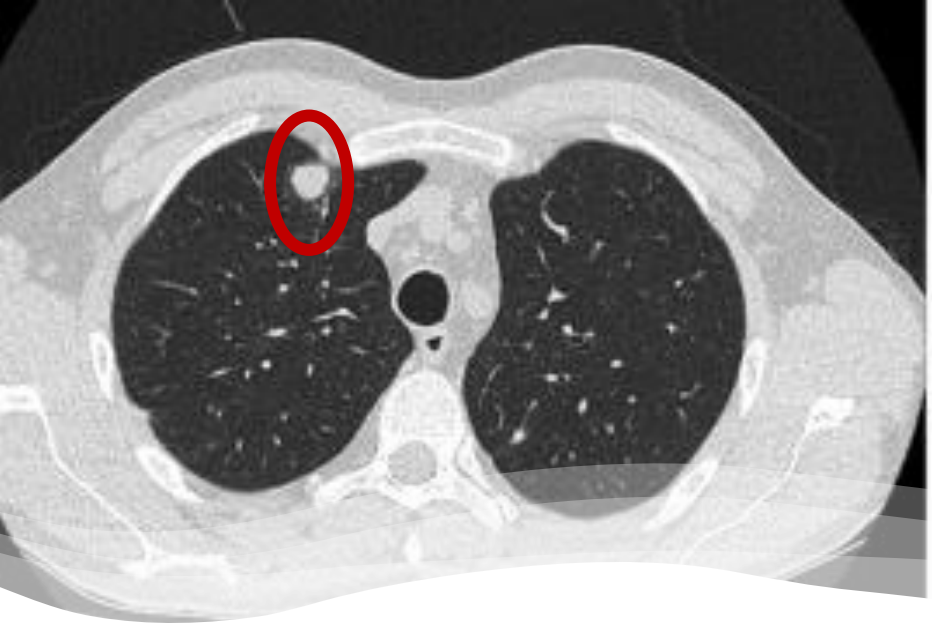

Granulomatous nodules

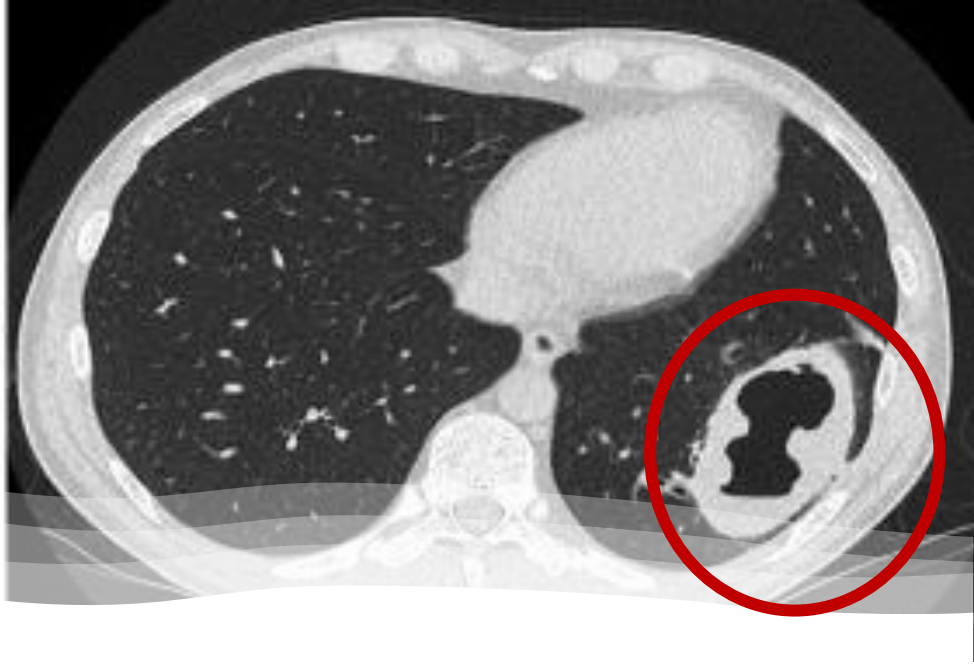

Cavitary nodule with necrosis

Sacoto G, Boukhlal S, Specks U, Flores-Suárez LF, Cornec D. Lung involvement in ANCA-associated vasculitis. Presse Med. 2020 Oct;49(3):104039. doi: 10.1016/j.lpm.2020.104039. Epub 2020 Jul 7. PMID: 32650042.

Diffuse Alveolar Hemorrhage

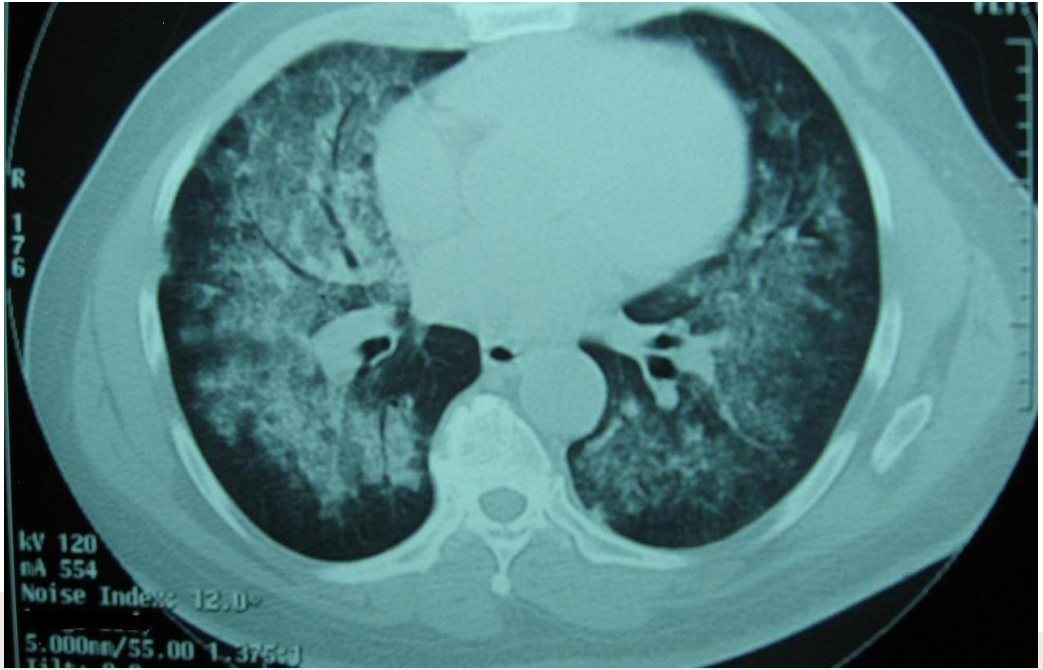

http://bjmp.org/files/2011-4-1/bjmp-2011-4-1-a402.pdf

Tracheobronchial inflammation

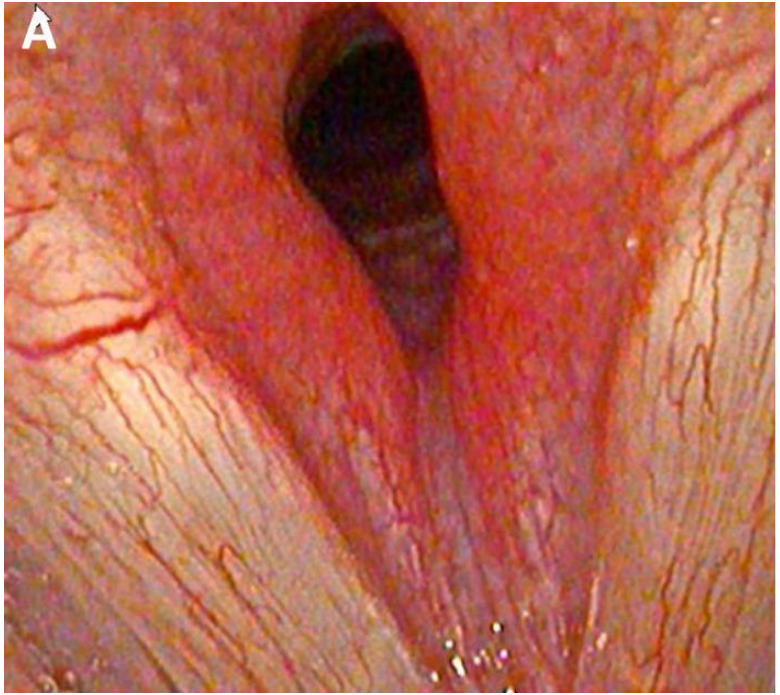

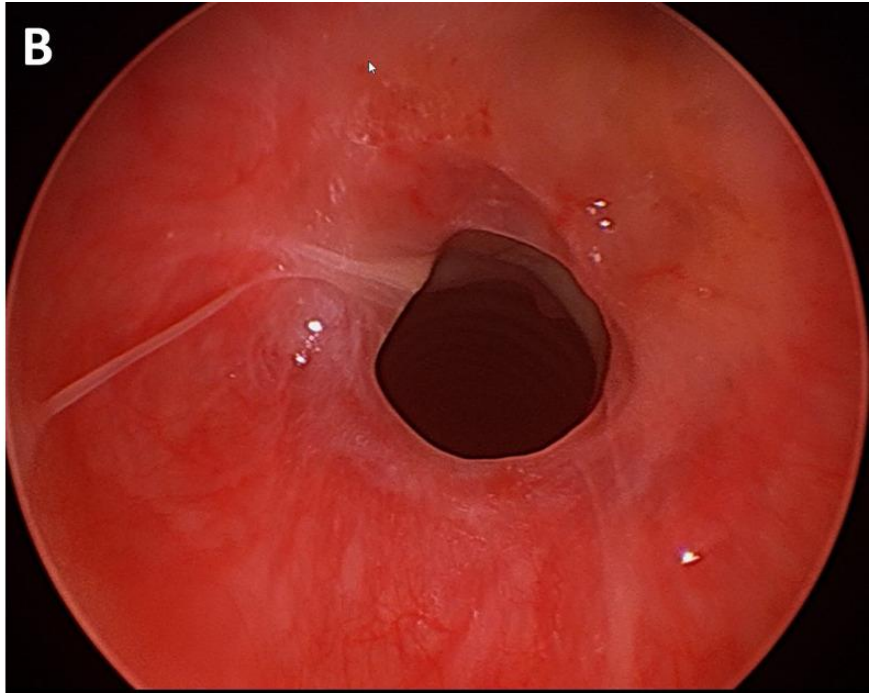

Sacoto G, Boukhlal S, Specks U, Flores-Suárez LF, Cornec D. Lung involvement in ANCA-associated vasculitis. Presse Med. 2020 Oct;49(3):104039. doi: 10.1016/j.lpm.2020.104039. Epub 2020 Jul 7. PMID: 32650042.

Interstitial Lung Disease (ILD)

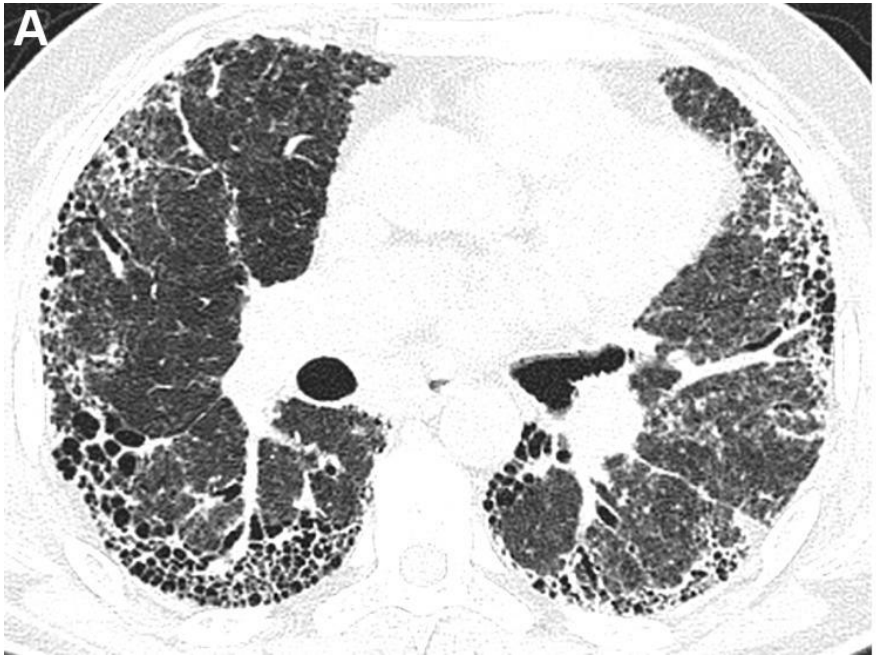

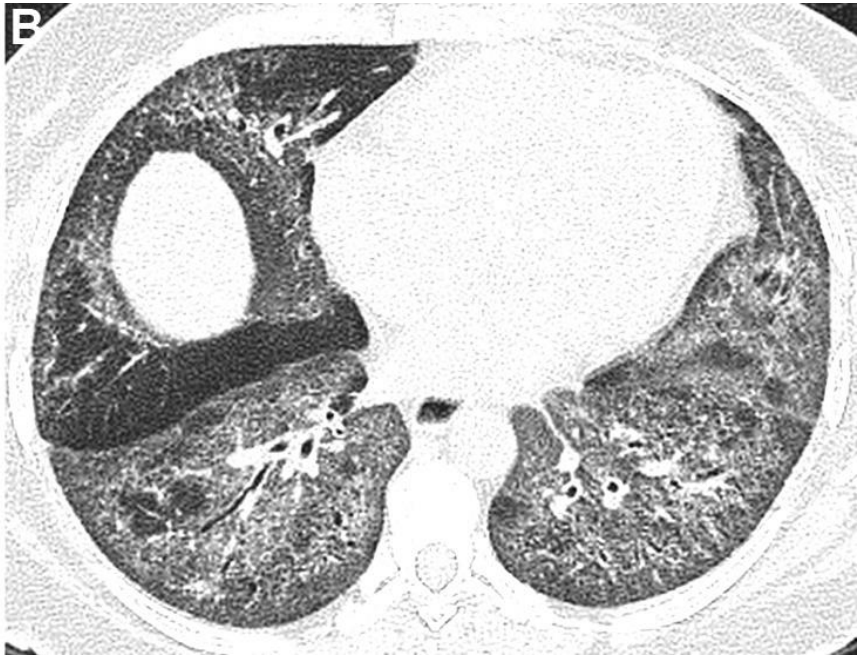

Sacoto G, Boukhlal S, Specks U, Flores-Suárez LF, Cornec D. Lung involvement in ANCA-associated vasculitis. Presse Med. 2020 Oct;49(3):104039. doi: 10.1016/j.lpm.2020.104039. Epub 2020 Jul 7. PMID: 32650042.

Laboratory work-up

1. ANCA
2. ANA
3. Anti-GBM antibodies
4. Sm/RNP ab
5. Cardiolipin ab, lupus anticoagulant, Beta-2 glycoprotein-1 ab

Other diagnostic work-up

1. Bronchoscopy: Helpful in visualizing the larynx, trachea, lungs, and bronchioles

2. Bronchoalveolar lavage (BAL)

3. Transbronchial or endobronchial biopsies: Helpful in ruling out malignancy and infection

Our patient

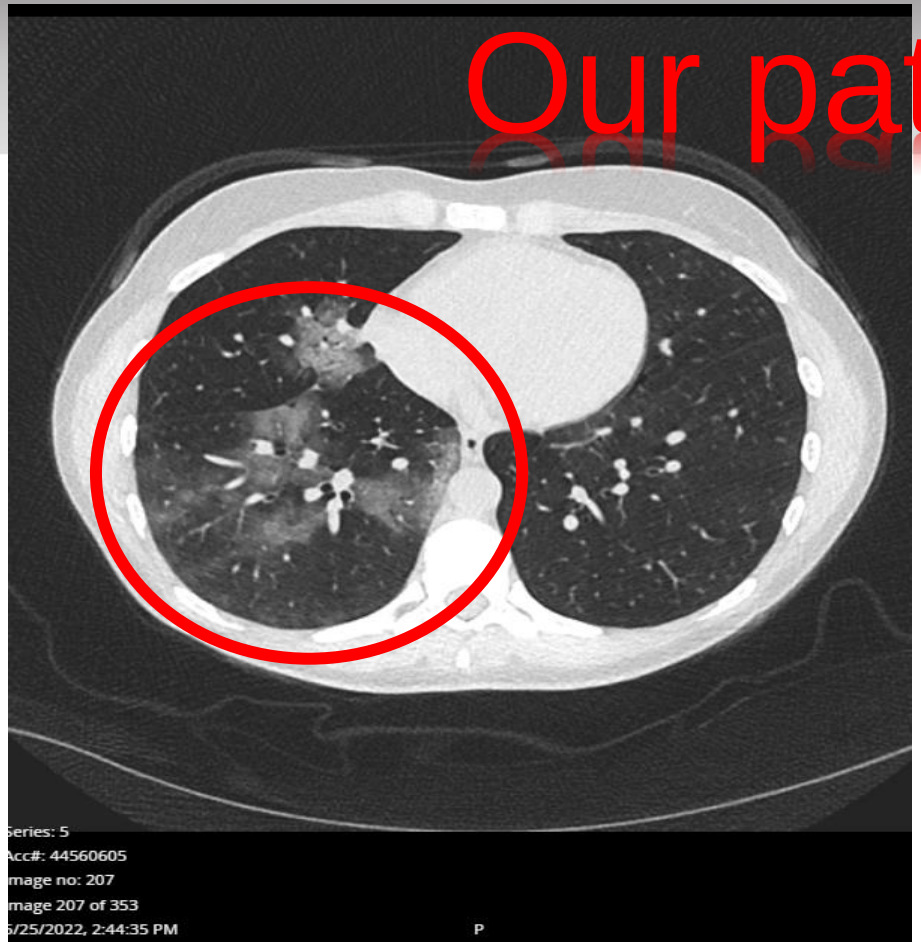
Series: 5
Acc#: 44560605
Image no: 207
Image 207 of 353
5/25/2022, 2:44:35 PM
P

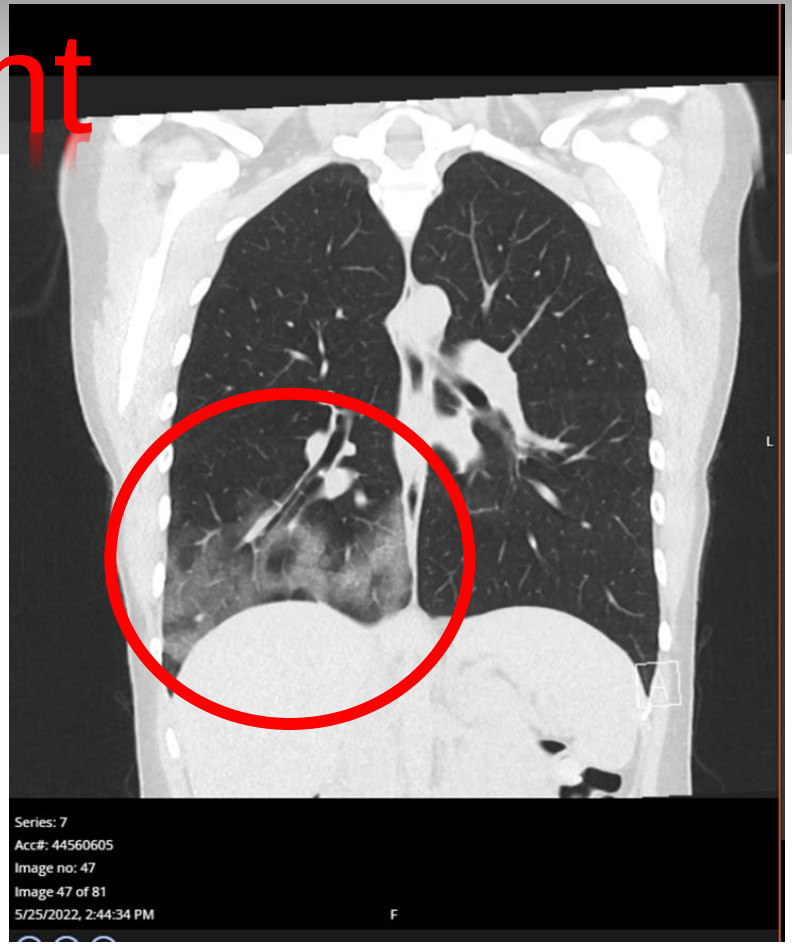
L
Series: 7
Acc#: 44560605
Image no: 47
Image 47 of 81
5/25/2022, 2:44:34 PM
F

Diffuse Alveolar Hemorrhage: Differential Diagnoses

AUTOIMMUNE	INFECTION	OTHER

What do YOU think??

von Ranke FM, Zanetti G, Hochhegger B, Marchiori E. Infectious diseases causing diffuse alveolar hemorrhage in immunocompetent patients: a state-of-the-art review. Lung. 2013 Feb;191(1):9-18. doi: 10.1007/s00408-012-9431-7. Epub 2012 Nov 6. PMID: 23128913; PMCID: PMC7102311.
Park MS. Diffuse alveolar hemorrhage. Tuberc Respir Dis (Seoul). 2013 Apr;74(4):151-62. doi: 10.4046/trd.2013.74.4.151. Epub 2013 Apr 30. PMID: 23678356; PMCID: PMC3651925.

Diffuse Alveolar Hemorrhage: Differential Diagnoses

AUTOIMMUNE	INFECTION	OTHER
Systemic vasculitides (GPA, EGPA, MPA)	**COVID**	Vaping
Cryoglobulinemia	**Viral:** influenza A, Ebola, Dengue, CMV, adenovirus	Drug toxicities
Goodpasture's	**Bacterial:** Leptospirosis, tuberculosis, staph aureus, Legionella	Malignancy
SLE	**Parasitic:** malaria, paragonimus, strongyloides	Pulmonary lymphoma
Antiphospholipid antibody syndrome	**Fungal**: aspergillosis	

von Ranke FM, Zanetti G, Hochhegger B, Marchiori E. Infectious diseases causing diffuse alveolar hemorrhage in immunocompetent patients: a state-of-the-art review. Lung. 2013 Feb;191(1):9-18. doi: 10.1007/s00408-012-9431-7. Epub 2012 Nov 6. PMID: 23128913; PMCID: PMC7102311.
Park MS. Diffuse alveolar hemorrhage. Tuberc Respir Dis (Seoul). 2013 Apr;74(4):151-62. doi: 10.4046/trd.2013.74.4.151. Epub 2013 Apr 30. PMID: 23678356; PMCID: PMC3651925.

Work-up continued: patient admitted

Admitted 5/25/2022

Bronchoscopy 5/26/22: BAL non-bloody. PCR + COVID-19

5/27/2022: Started remdesivir

5/28: Started ceftriaxone for CAP coverage

5/28: Smear positive for babesiosis.

5/29: Started atovaquone, azithromycin, doxycycline

5/30: Repeat chest CT scan – slight decrease in GGO

Discharged home 5/31

Final BAL results 6/1 (after discharge)

Diffuse alveolar hemorrhage??

Non-Gyn Cytology Report

Final Diagnosis

Bronchoalveolar lavage, right lower lobe:

No evidence of malignancy in this one specimen. Marked acute and chronic inflammation present.

No pneumocystis, fungus, or viral cytopathic effect identified.

Grocott stain is negative for Pneumocystis jiroveci with adequate control.

Iron stain is positive for few hemosiderin laden macrophages with adequate control.

Final Diagnosis ?

Infection secondary to babesiosis

DAH secondary to underlying diagnosis of GPA

Organizing pneumonia secondary to COVID-19

Could she have all 3 diagnoses concurrently?

What is babesiosis ?

- Tick borne virus caused by the parasite *Babesia microti*
- Transmitted by the deer tick
- Asymptomatic infection is common
- Up to 50% of patients will have Lyme co-infection
- Severe manifestations: ARDS, severe anemia, CHF, renal failure, DIC, splenic infarction
- Case reports of pulmonary edema
- ? Ground glass opacities
- Was babesiois found incidentally?

Vannier Edouard G. Babesiosis: Clinical manifestations and diagnosis. In: UptoDate, Baron El (Ed), UptoDate, Waltham, MA. (Accessed on July 11, 2022.)

COVID-19: Testing

Respir Med Case Rep. 2020; 30: 101120.
Published online 2020 Jun 8. doi: 10.1016/j.rmcr.2020.101120

PMCID: PMC7298516
PMID: 32566476

Detection of SARS-CoV-2 by bronchoscopy after negative nasopharyngeal testing: Stay vigilant for COVID-19

Kathleen J. Ramos,[a,*] Siddhartha G. Kapnadak,[a] Bridget F. Collins,[a] Paul S. Pottinger,[b] Richard Wall,[c] James A. Mays,[d] Garrett A. Perchetti,[d] Keith R. Jerome,[d,e] Sandeep Khot,[f] Ajit P. Limaye,[b] Patrick C. Mathias,[d,g] and Alexander Greninger[d,e]

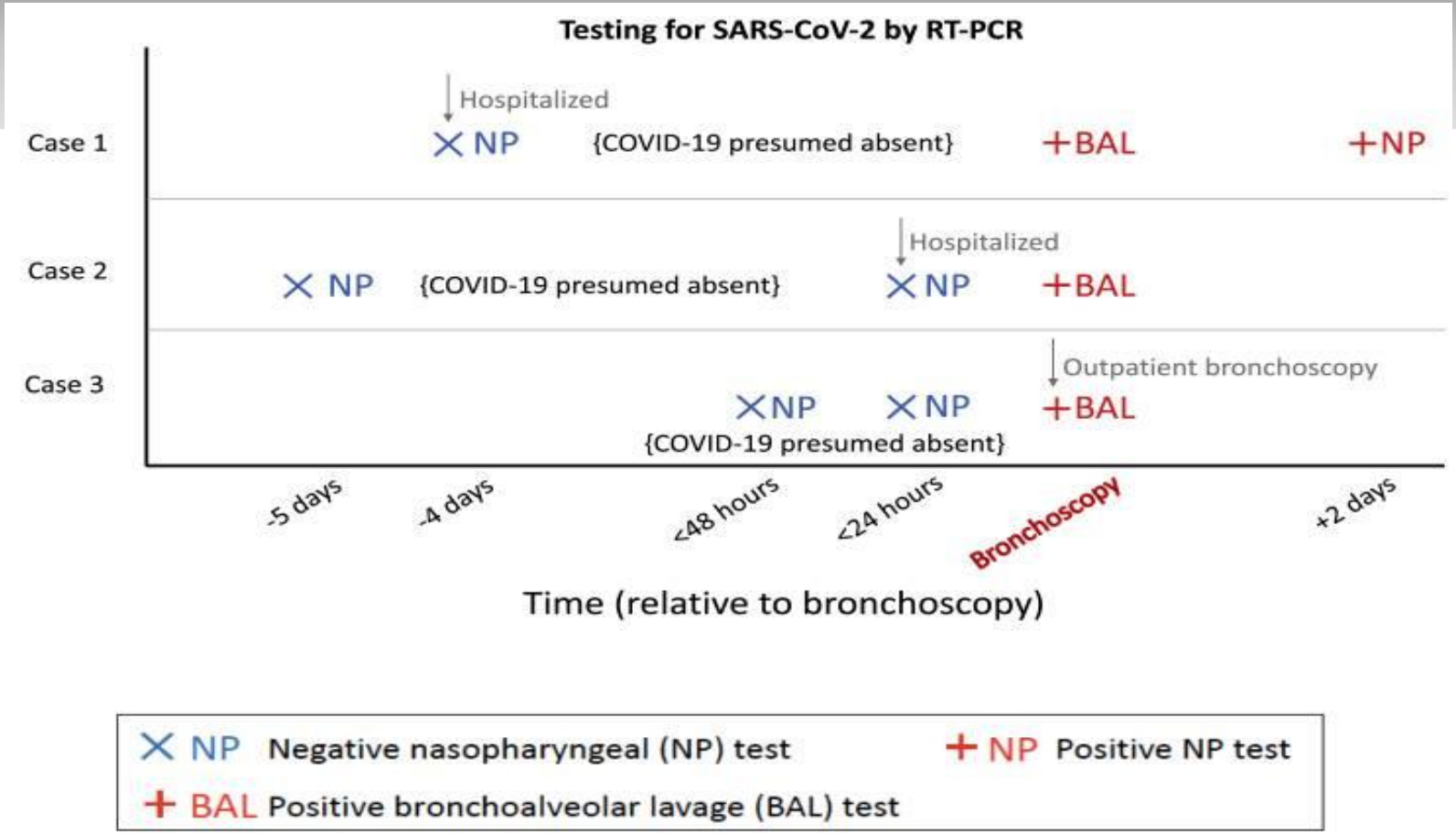

Ramos KJ, Kapnadak SG, Collins BF, Pottinger PS, Wall R, Mays JA, Perchetti GA, Jerome KR, Khot S, Limaye AP, Mathias PC, Greninger A. Detection of SARS-CoV-2 by bronchoscopy after negative nasopharyngeal testing: Stay vigilant for COVID-19. Respir Med Case Rep. 2020 Jun 8;30:101120. doi: 10.1016/j.rmcr.2020.101120. PMID: 32566476; PMCID: PMC7298516.

Hematol Oncol Stem Cell Ther. 2021 Mar; 14(1): 65–70.
Published online 2020 Oct 8. doi: 10.1016/j.hemonc.2020.09.002

PMCID: PMC7543702
PMID: 33058787

Bronchoalveolar lavage-based COVID-19 testing in patients with cancer

Muhammad Bilal Abid,[a,b,*] Saurabh Chhabra,[b] Blake Buchan,[c] Mary Beth Graham,[a] Sameem Abedin,[b] Bicky Thapa,[b] Anita D'Souza,[b] Ben George,[b] and Mehdi Hamadani[b]

▸ Author information ▸ Article notes ▸ Copyright and License information Disclaimer

Abstract

Go to: ▸

Objective/Background

A few case reports in the setting of coronavirus disease 2019 (COVID-19) and multiplex polymerase chain reaction (PCR)-based assays for common respiratory pathogens have shown a higher yield of bronchoalveolar lavage (BAL) samples than upper airway specimens in immunocompromised patients.

Abid MB, Chhabra S, Buchan B, Graham MB, Abedin S, Thapa B, D'Souza A, George B, Hamadani M. Bronchoalveolar lavage-based COVID-19 testing in patients with cancer. Hematol Oncol Stem Cell Ther. 2021 Mar;14(1):65-70. doi: 10.1016/j.hemonc.2020.09.002. Epub 2020 Oct 8. PMID: 33058787; PMCID: PMC7543702.

	Patient 1	Patient 2	Patient 3
Day of symptoms when tested positive for COVID-19	Day 8 (Positive from BAL; NP swab negative 4 times while inpatient)	Day 10	Day 8
Source of testing	BAL	BAL	BAL
Days between first negative NP swab and positive BAL	6 weeks	3 days	2 days
Number of negative NP swabs before positive BAL	4	1	1
Admission CXR/Chest CT	Bilateral GGO with cavitation	Bilateral GGO with consolidative opacities	Bilateral GGO with consolidative opacities

Abid MB, Chhabra S, Buchan B, Graham MB, Abedin S, Thapa B, D'Souza A, George B, Hamadani M. Bronchoalveolar lavage-based COVID-19 testing in patients with cancer. Hematol Oncol Stem Cell Ther. 2021 Mar;14(1):65-70. doi: 10.1016/j.hemonc.2020.09.002. Epub 2020 Oct 8. PMID: 33058787; PMCID: PMC7543702.

Our patient – post hospitalization

1. COVID-19

- Completed 5 day course of Remdesivir
- Discharged on ceftriaxone for CAP coverage
- Hold methotrexate until course completed.

2. Babesiosis

- Atovaquone 750mg PO twice daily
- Azithromycin 500mg PO daily
- Doxycycline 100mg twice daily for empiric coverage of other tick bone illnesses
- Continue on medications for 2-4 weeks until repeat smear

3. Granulomatosis with Polyangiitis

- Repeat chest CT scan in 4 weeks
- Plan to repeat rituximab at the end of August
- Possible DAH → check labs once a week to monitor H/H

Summary

When evaluating a patient with vasculitis:

Avoid assuming that all new symptoms are due to vasculitis

Avoid treating for vasculitis in the absence of definitive proof for active disease

Be aware that vasculitis and mimics can co-exist

References

1. Abid MB, Chhabra S, Buchan B, Graham MB, Abedin S, Thapa B, D'Souza A, George B, Hamadani M. Bronchoalveolar lavage-based COVID-19 testing in patients with cancer. Hematol Oncol Stem Cell Ther. 2021 Mar;14(1):65-70. doi: 10.1016/j.hemonc.2020.09.002. Epub 2020 Oct 8. PMID: 33058787; PMCID: PMC7543702.
2. Parekh M, Donuru A, Balasubramanya R, Kapur S. Review of the Chest CT Differential Diagnosis of Ground-Glass Opacities in the COVID Era. Radiology. 2020 Dec;297(3):E289-E302. doi: 10.1148/radiol.2020202504. Epub 2020 Jul 7. PMID: 32633678; PMCID: PMC7350036.
3. Park MS. Diffuse alveolar hemorrhage. Tuberc Respir Dis (Seoul). 2013 Apr;74(4):151-62. doi: 10.4046/trd.2013.74.4.151. Epub 2013 Apr 30. PMID: 23678356; PMCID: PMC3651925.
4. Ramos KJ, Kapnadak SG, Collins BF, Pottinger PS, Wall R, Mays JA, Perchetti GA, Jerome KR, Khot S, Limaye AP, Mathias PC, Greninger A. Detection of SARS-CoV-2 by bronchoscopy after negative nasopharyngeal testing: Stay vigilant for COVID-19. Respir Med Case Rep. 2020 Jun 8;30:101120. doi: 10.1016/j.rmcr.2020.101120. PMID: 32566476; PMCID: PMC7298516.
5. Sacoto G, Boukhlal S, Specks U, Flores-Suárez LF, Cornec D. Lung involvement in ANCA-associated vasculitis. Presse Med. 2020 Oct;49(3):104039. doi: 10.1016/j.lpm.2020.104039. Epub 2020 Jul 7. PMID: 32650042.
6. Sebastiani M, Manfredi A, Vacchi C, Cassone G, Faverio P, Cavazza A, Sverzellati N, Salvarani C, Luppi F. Epidemiology and management of interstitial lung disease in ANCA-associated vasculitis. Clin Exp Rheumatol. 2020 Mar-Apr;38 Suppl 124(2):221-231. Epub 2020 Apr 22. PMID: 32324122.
7. http://bjmp.org/files/2011-4-1/bjmp-2011-4-1-a402.pdf
8. Vannier Edouard G. Babesiosis: Clinical manifestations and diagnosis. In: UptoDate, Baron El (Ed), UptoDate, Waltham, MA. (Accessed on July 11, 2022.)
9. von Ranke FM, Zanetti G, Hochhegger B, Marchiori E. Infectious diseases causing diffuse alveolar hemorrhage in immunocompetent patients: a state-of-the-art review. Lung. 2013 Feb;191(1):9-18. doi: 10.1007/s00408-012-9431-7. Epub 2012 Nov 6. PMID: 23128913; PMCID: PMC7102311.

When you order something online vs. when it arrives

Penn Medicine