RhAPP

RHEUMATOLOGY ADVANCED PRACTICE PROVIDERS

Inaugural National Conference

December 3 – 5, 2020

VIRTUAL CONFERENCE

RhAPP
RHEUMATOLOGY ADVANCED PRACTICE PROVIDERS

Autoimmune Related Pulmonary Diseases

Katie Rosen, RN, MSN, ANP-C
National Jewish Health
Interstitial Lung Disease Program

Disclosure

All faculty and staff involved in the planning or presentation of continuing education activities provided by the Annenberg Center for Health Sciences at Eisenhower (ACHS) are required to disclose to the audience any real or apparent commercial financial affiliations related to the content of the presentation or enduring material. Full disclosure of all commercial relationships must be made in writing to the audience prior to the activity. All staff at the Annenberg Center for Health Sciences at Eisenhower and Rheumatology Advanced Practice Providers (RhAPP) have no relationships to disclose.

NO DISCLOSURES TO REPORT

Faculty Disclosures

Katie Rosen, RN, MSN, ANP-C

- There are no relationships to disclose.

OBJECTIVES

- RECOGNITION OF PULMONARY INVOLVEMENT IN CTD
- CLARIFY LUNG COMPARTMENTS AFFECTED BY AUTOIMMUNE DISEASE
- DEFINITION OF COMMON ACRONYMS
- COMMON AUTOIMMUNE DISEASES AND RESPECTIVE PULMONARY MANIFESTATIONS (RA, SCLERODERMA, PM/DM, SJOGREN'S, LUPUS)
- UPDATE ON ANTIFIBROTIC THERAPY
- PALLIATIVE CARE CONSIDERATION

Case

30-ish year old woman. Hx RA.

Rx: Pred 5mg + adalimumab.

CC: dyspnea w/exertion

Exam: +Digital clubbing, insp. crackles

HRCT: Upper/mid lung predominant reticulation w/traction bronchiectasis, superimposed GGO.

IMPORTANCE OF EVALUATING LUNG INVOLVEMENT

- Lung involvement possible in all CTD's
- RA-lung involvement 2nd leading cause of death
- SSc-ILD is the leading cause of death

LUNG COMPARTMENTS

PLEURA

AIRWAYS

INTERSTITIUM

VASCULATURE

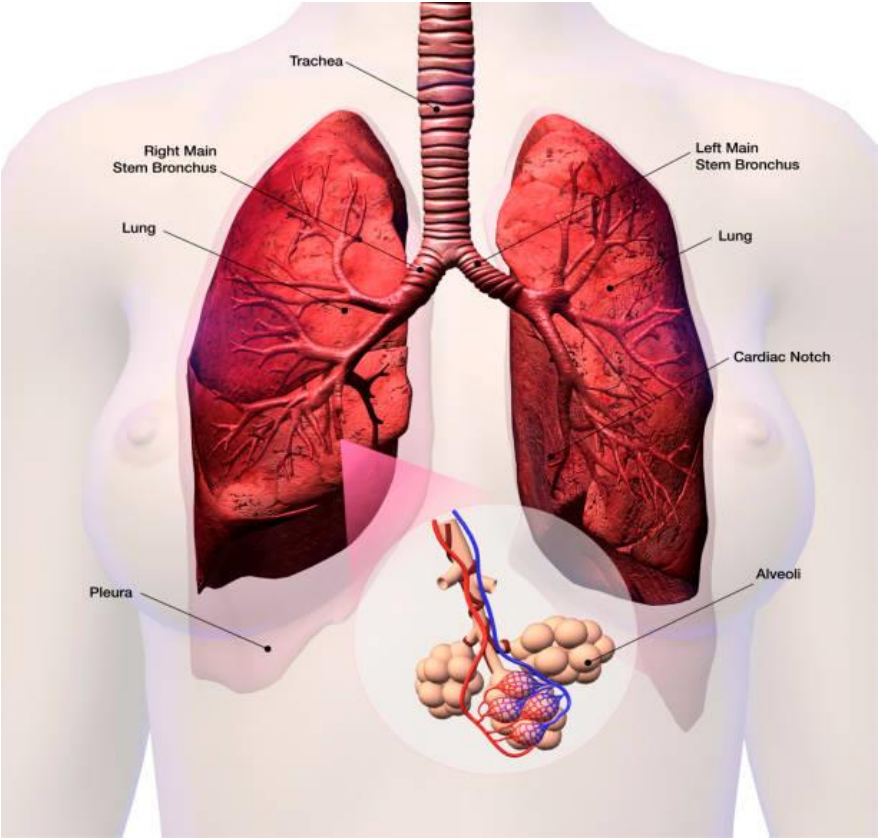

LET ME COUNT THE WAYS

	ILD	Airways	Pleural	Vascular	DAH
Systemic sclerosis	+++	–	–	+++	–
Rheumatoid arthritis	++	++	++	+	–
Primary Sjögren's syndrome	++	++	+	+	–
Mixed CTD	++	+	+	++	–
Polymyositis/ dermatomyositis	+++	–	–	+	–
Systemic lupus erythematosus	+	+	+++	+	++

The signs show prevalence of each manifestation (–=no prevalence; +=low prevalence; ++=medium prevalence; +++=high prevalence). ILD=interstitial lung disease. DAH=diffuse alveolar haemorrhage. CTD=connective tissue disease.

Table 1: **CTDs and common pulmonary manifestations**

Fischer A and Du Bois R. *Lancet* 2012; 380: 689-698

INTERSTITIAL COMPARTMENT

ILD: Broad group of diseases that cause inflammation and/or fibrosis in lung parenchyma

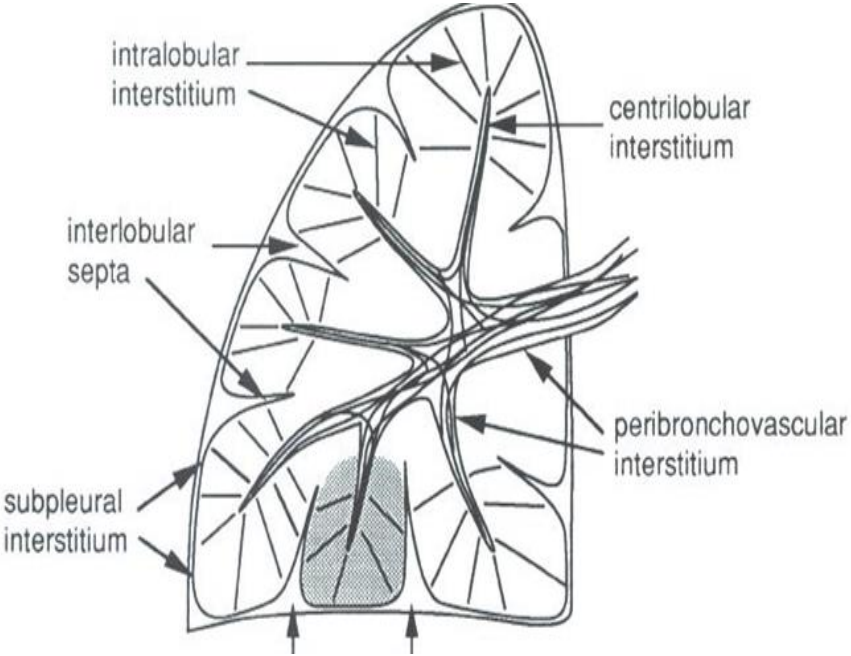

CATEGORIES OF ILD

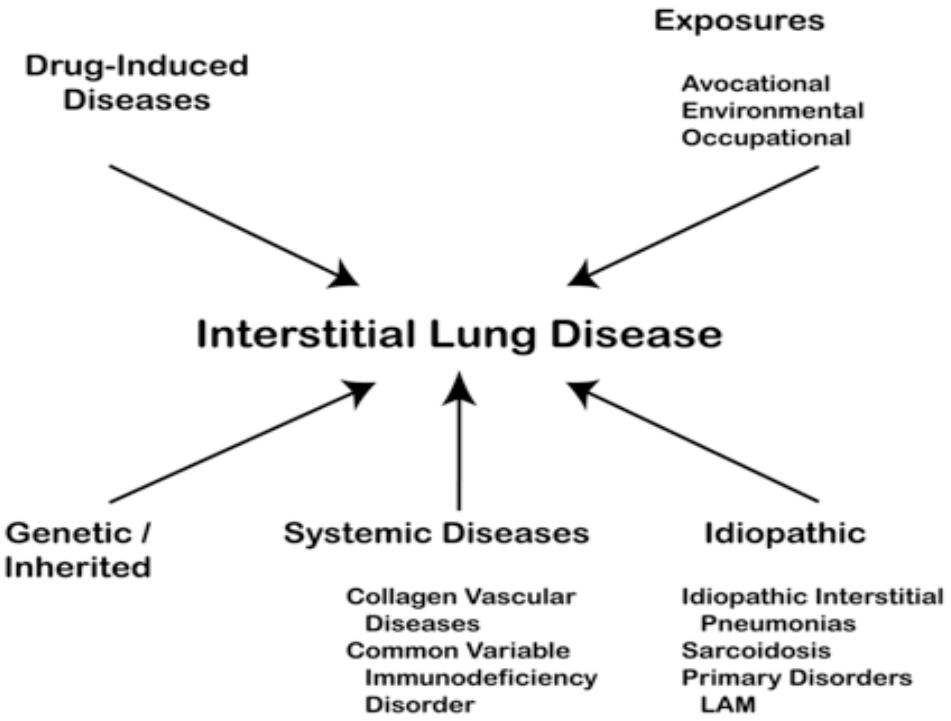

COMMON ACRONYMS of ILD



COMMON ACRONYMS of ILD



UIP- Usual interstitial pneumonia: *Reticular opacities in a basal/peripheral pattern, subpleural honeycombing, traction bronchiectasis.*

COMMON ACRONYMS of ILD



UIP- Usual interstitial pneumonia: *Reticular opacities in a basal/peripheral pattern, subpleural honeycombing, traction bronchiectasis.*

NSIP- Nonspecific interstitial pneumonia: *chronic interstitial pneumonia w/homogeneous interstitial fibrosis and inflammation. Usually bilat.*

COMMON ACRONYMS of ILD



OB/BO- Obliterative Bronchiolitis/Bronchiolitis Obliterans *small airways injury: CTD, infxn.,inhaled, transplant*

UIP- Usual interstitial pneumonia: *Reticular opacities in a basal/peripheral pattern, subpleural honeycombing, traction bronchiectasis.*

NSIP- Nonspecific interstitial pneumonia: *chronic interstitial pneumonia w/homogeneous interstitial fibrosis and inflammation. Usually bilat.*

COMMON ACRONYMS of ILD



OB/BO- Obliterative Bronchiolitis/Bronchiolitis Obliterans *small airways injury: CTD, infxn.,inhaled, transplant*

LIP- Lymphoid Interstitial Pneumonia *Pulmonary infiltrates caused by lymphocytes/plasma cells. Can lead to fibrosis or cysts.*

UIP- Usual interstitial pneumonia: *Reticular opacities in a basal/peripheral pattern, subpleural honeycombing, traction bronchiectasis.*

NSIP- Nonspecific interstitial pneumonia: *chronic interstitial pneumonia w/homogeneous interstitial fibrosis and inflammation. Usually bilat.*

COMMON ACRONYMS of ILD



UIP- Usual interstitial pneumonia: *Reticular opacities in a basal/peripheral pattern, subpleural honeycombing, traction bronchiectasis.*

NSIP- Nonspecific interstitial pneumonia: *chronic interstitial pneumonia w/homogeneous interstitial fibrosis and inflammation. Usually bilat.*

OB/BO- Obliterative Bronchiolitis/Bronchiolitis Obliterans *small airways injury: CTD, infxn.,inhaled, transplant*

LIP- Lymphoid Interstitial Pneumonia *Pulmonary infiltrates caused by lymphocytes/plasma cells. Can lead to fibrosis or cysts.*

OP- Organizing pneumonia- *Excess granulation tissue in small airways, into alveoli*

COMMON ACRONYMS of ILD



UIP- Usual interstitial pneumonia: *Reticular opacities in a basal/peripheral pattern, subpleural honeycombing, traction bronchiectasis.*

NSIP- Nonspecific interstitial pneumonia: *chronic interstitial pneumonia w/homogeneous interstitial fibrosis and inflammation. Usually bilat.*

OB/BO- Obliterative Bronchiolitis/Bronchiolitis Obliterans *small airways injury: CTD, infxn.,inhaled, transplant*

LIP- Lymphoid Interstitial Pneumonia *Pulmonary infiltrates caused by lymphocytes/plasma cells. Can lead to fibrosis or cysts.*

OP- Organizing pneumonia- *Excess granulation tissue in small airways, into alveoli*

DAH- Diffuse alveolar hemorrhage -*Bleeding into the alveolar space -*

COMMON ACRONYMS of ILD



UIP- Usual interstitial pneumonia: *Reticular opacities in a basal/peripheral pattern, subpleural honeycombing, traction bronchiectasis.*

NSIP- Nonspecific interstitial pneumonia: *chronic interstitial pneumonia w/homogeneous interstitial fibrosis and inflammation. Usually bilat.*

OB/BO- Obliterative Bronchiolitis/Bronchiolitis Obliterans *small airways injury: CTD, infxn.,inhaled, transplant*

LIP- Lymphoid Interstitial Pneumonia *Pulmonary infiltrates caused by lymphocytes/plasma cells. Can lead to fibrosis or cysts.*

OP- Organizing pneumonia- *Excess granulation tissue in small airways, into alveoli*

DAH- Diffuse alveolar hemorrhage -*Bleeding into the alveolar space*

DAD- Diffuse alveolar damage - *Edema of alveolar septa and development of hyaline membranes*

Normal vs. NSIP imaging pattern

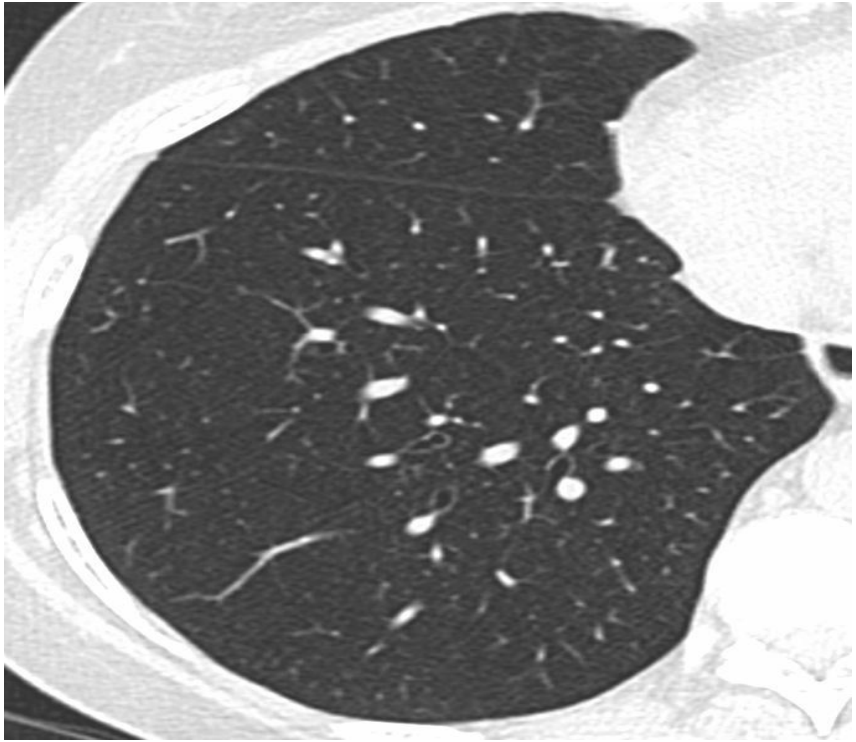

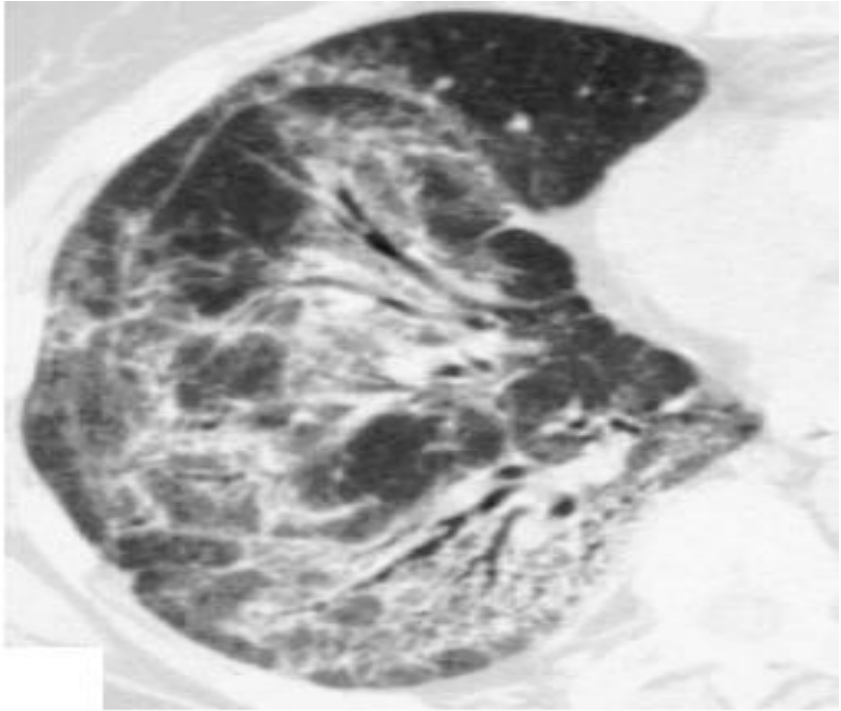

UIP vs. NSIP imaging patterns

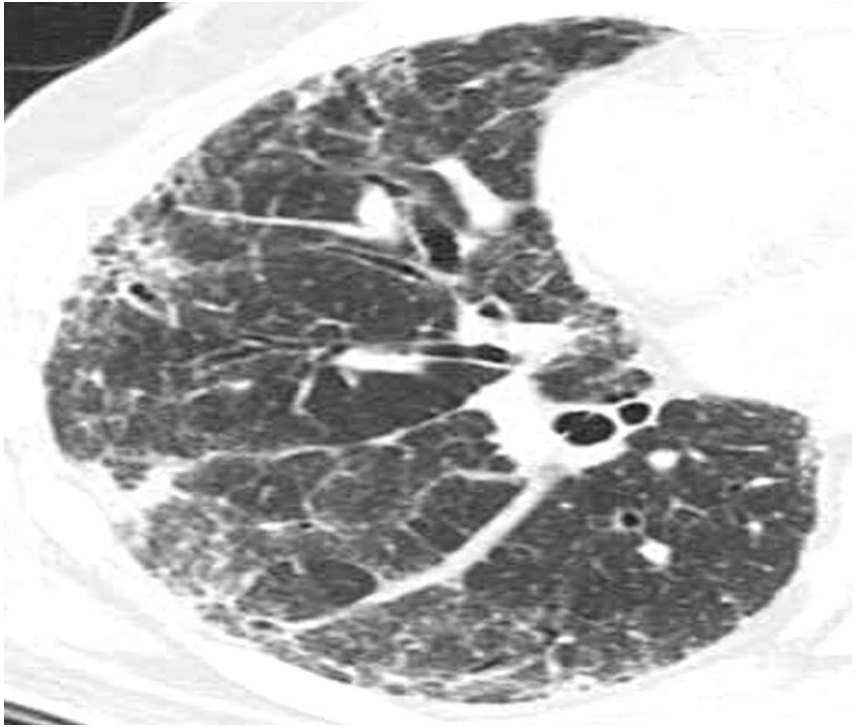

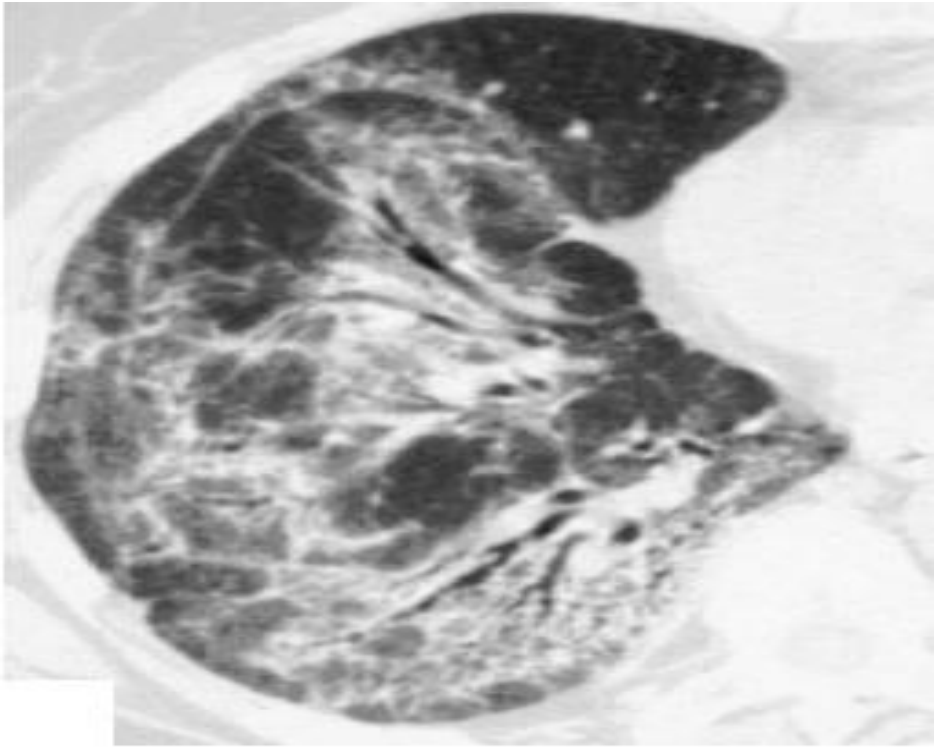

ORGANIZING PNEUMONIA

CAUSES?

- Infection
- Aspiration
- HP (hypersensitivity pneumonitis)
- CTD
- Eosinophilic PNA
- COP

DIFFUSE ALVEOLAR DAMAGE

CAUSES:

- Infection
- Sepsis
- CTD
- Drug toxicity
- Radiation pneumonitis
- Toxic inhalant
- Trauma
- AIP
- Idiopathic

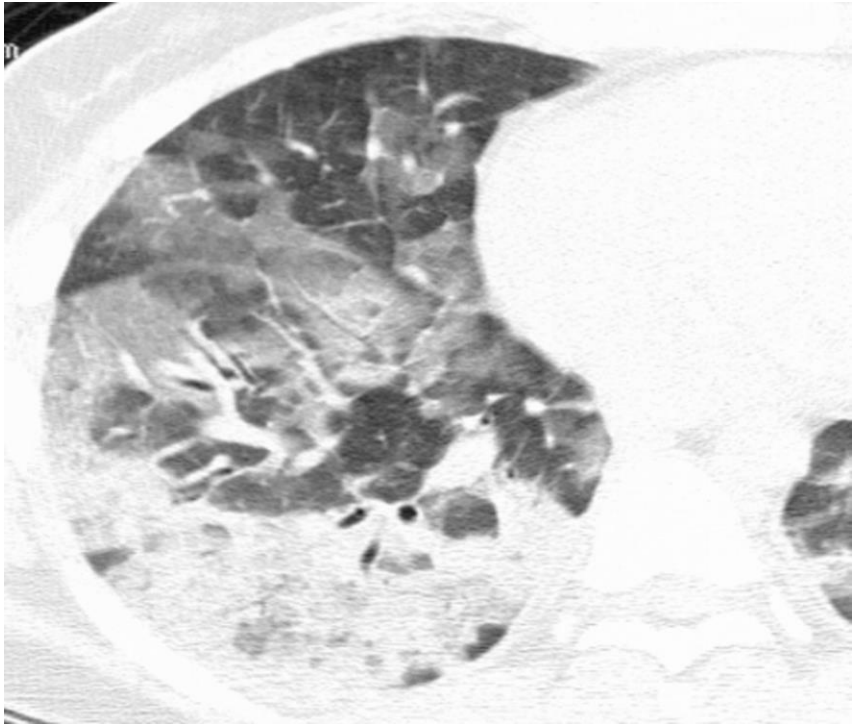

PULMONARY EVALUATION-HRCT

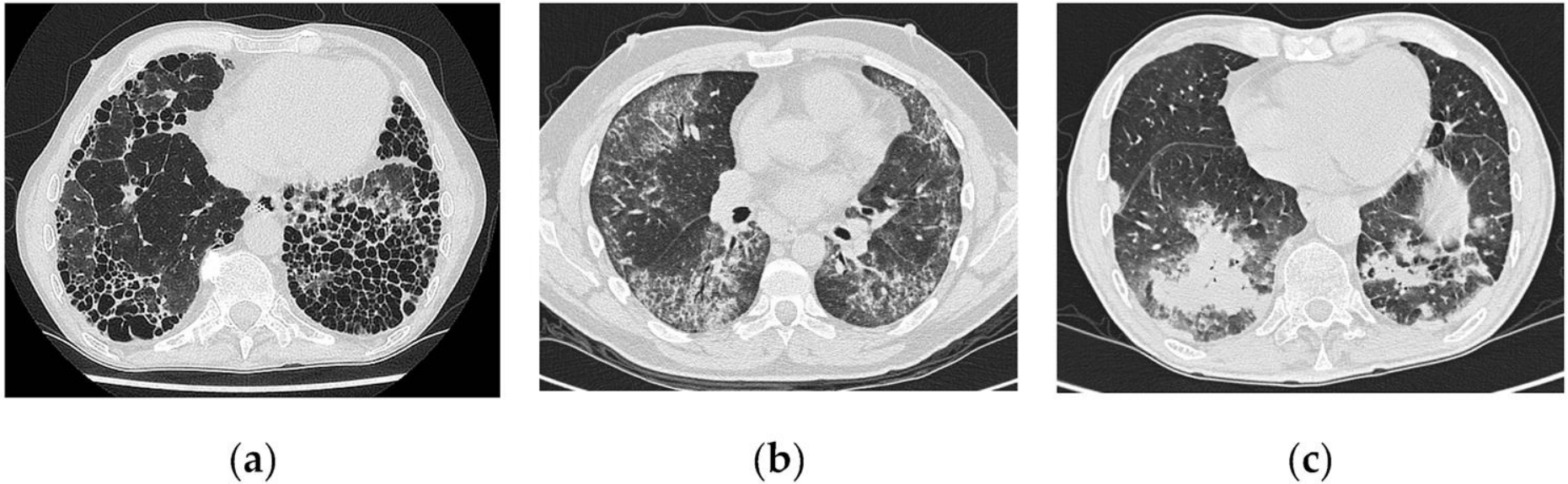

IMAGE: Bendstrup E, Møller J, Kronborg-White S, Prior TS, Hyldgaard C. Interstitial Lung Disease in Rheumatoid Arthritis Remains a Challenge for Clinicians. J Clin Med. 2019 Nov 21;8(12):2038. doi: 10.3390/jcm8122038. PMID: 31766446; PMCID: PMC6947091.

RHEUMATOID ARTHRITIS

- **Airways**
  - upper, lower, small
  - bronchiolitis can be cellular or fibrotic
- **Pleura**
  - Pleurisy, Pleuritis
  - Effusions
    - need to r/o other causes (HF, infxn)
- **Vasculature**
  - Capillaritis
  - Alveolar hemorrhage
  - Primary PH less common, but consider PH if underlying ILD
- **Parenchyma (ILD)**
  - **UIP**
  - NSIP
  - OP
  - LIP
  - DAH
  - Nodules
- ***Consider other pulmonary issues***…
  - infection
  - drug toxicity

RHEUMATOID ARTHRITIS

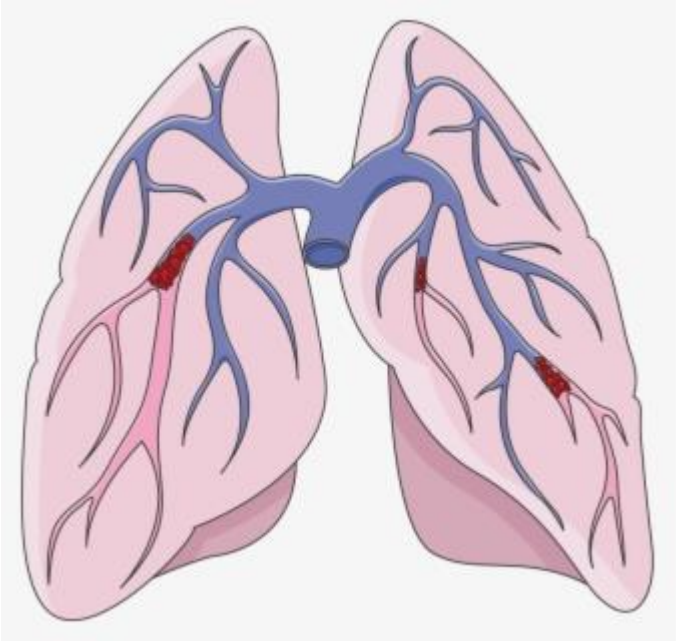

- **INCREASED RISK FOR DVT and PE**
  - **Chung et al - Increased risk for DVT: 3.36-fold and PE: 2.07-fold**
- **INCREASED RISK FOR CANCER**
  - **Simon et al - Increased risk for lung cancer & lymphomas**

SCLERODERMA (SSc)

ILD

- NSIP more common than UIP

PAH

- Remodeling of vessels
- Untreated→RHF→death

Increased mortality:
+SCL-70, ↓DLCO,CT-extent disease, ↑cutaneous sclerosis, ↓FVC & DLCO over 2 yr, ↑age

Treatment: patients w/progressive disease

- Steroids?Controversial, ↑risk renal crisis
- Cytoxan, MMF, AZA, Ritux
- Ofev-may slow progression
- Close monitoring-every 3 months
  - FVC/DLCO
  - 6mwt

Fischer et al, Vacchi et al

SCLERODERMA

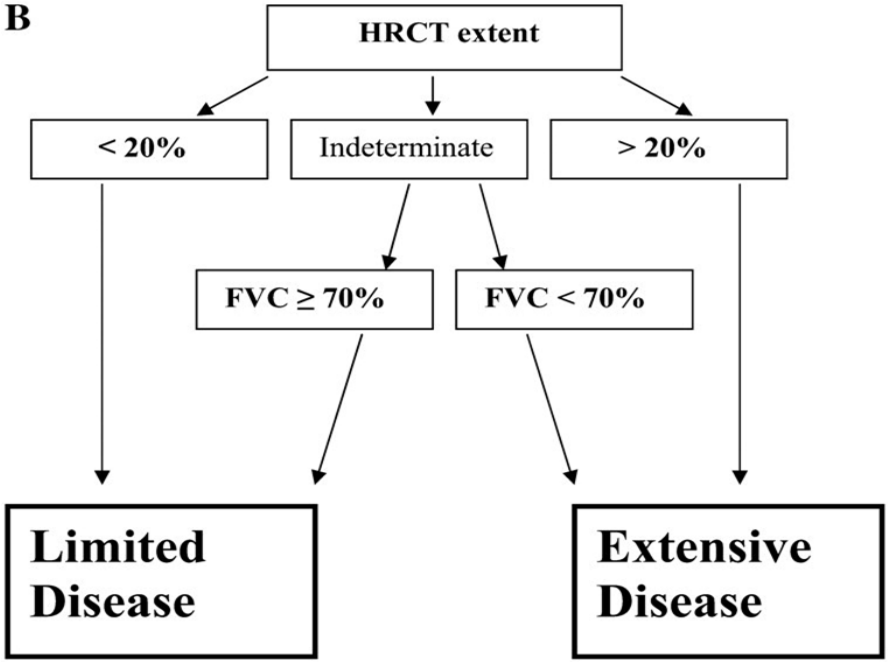

Goh et al, 2008

SCLERODERMA SURVIVAL

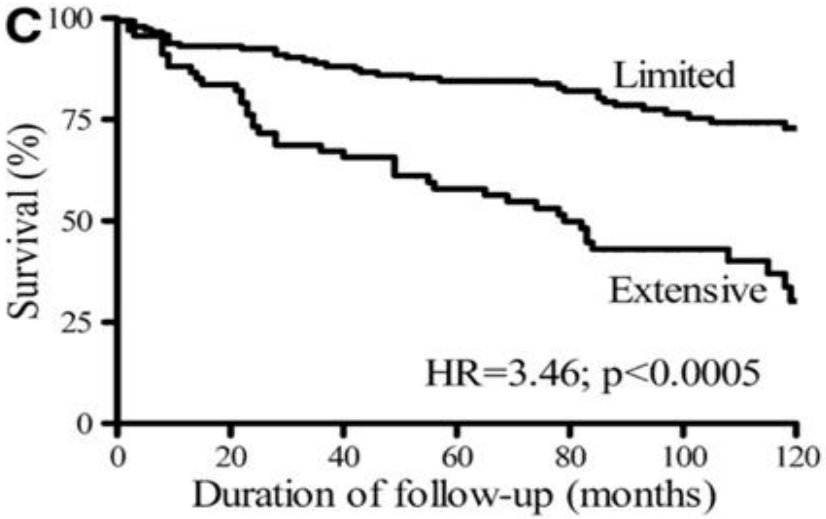

Figure 4. Survival compared between patient subgroups with (*A*) FVC levels above and below a threshold value of 70%, (*B*) high-resolution computed tomography (HRCT) disease extent above and below a threshold value of 20%, and (*C*) limited disease (HRCT extent ≤ 10% or, when HRCT extent was 10–30%, FVC ≥ 70%) versus extensive disease (HRCT > 30% or, when HRCT extent was 10–30%, FVC < 70%). ext = extent.

Am J Respir Crit Care Med,
https://www.atsjournals.org/doi/abs/10.1164/rccm.200706-877OC

Published in: Nicole S. L. Goh; Sujal R. Desai; Srihari Veeraraghavan; David M. Hansell; Susan J. Copley; Toby M. Maher; Tamera J. Corte; Clare R. Sander; Jonathan Ratoff; Anand Devaraj; Gracijela Bozovic; Christopher P. Denton; Carol M. Black; Roland M. du Bois; Athol U. Wells; *Am J Respir Crit Care Med* 2008 1771248-1254.
DOI: 10.1164/rccm.200706-877OC

POLYMYOSITIS/DERMATOMYOSITIS

Pleura/airways-not common

ILD (NSIP, UIP, OP, DAD, AIP)

Lung involvement-leading cause of death (may be direct (disease) or indirect (pneumonia)

Treatment: Immune suppression

- steroids
- MMF
- Azathioprine
- Cyclophosphamide
- Rituximab

SJOGREN'S SYNDROME

PH: rare

Airways: Chronic cough (50%), Xerotrachea,↓mucociliary clearance, bronchiolitis

Pleura: rare. Pleurisy or

Effusions

ILD: NSIP or LIP are most common, UIP, OP, amyloid, lymphoma

TREATMENT:

Steroids, MMF, AZA, Cyclophosphamide, Ritux

LUPUS

PLEURA: Pleural disease most common; pleuritis w or w/o effusions

AIRWAYS: Bronchiectasis (unclear if significant)

ILD: NSIP, may have OP, UIP, LIP (in sec. Sjogren's) Fibrosis less likely, may be peripheral, basal

VASCULATURE: Pulmonary hemorrhage. Consider also PE risk with antiphospholipid syndrome

What is a shrinking lung?

SOB, Restrictive physiology, Elevated diaphragm

TX: Steroids, immune suppression

ROLE OF ANTIFIBROTIC THERAPY

OFEV (nintedanib):

INBUILD study; slowed rate of decline in progressive fibrosing lung disease

- Does not reverse fibrosis
- Diarrhea common
- Monitor LFT’s

DRUG TOXICITY

Common drugs:

Amiodarone, Nitrofurantoin,
Bleomycin
TNFα

Methotrexate**

-Can get hypersensitivity w/cough,SOB, fever, ↑eos

-Juge et al 2020, MTX ILD not a/w ↑ ILD

Check pneumotox

PALLIATIVE CARE-QUALITY OF LIFE

SYMPTOMS ASSOCIATED WITH FIBROTIC ILD

- Anxiety
- Depression
- Cough
- Dyspnea→Hypoxemia→Supplemental oxygen use
- Need for caregiver support

Multidisciplinary Team: clinician, nursing, SW, psychologist

- Pharmacologic-↓dose opiate,benzo (anxiety), consider bronchodilator, 02
- Psychosocial-Pulm rehab (may be difficult for adv.CTD), CBT, cool fan, energy conservation

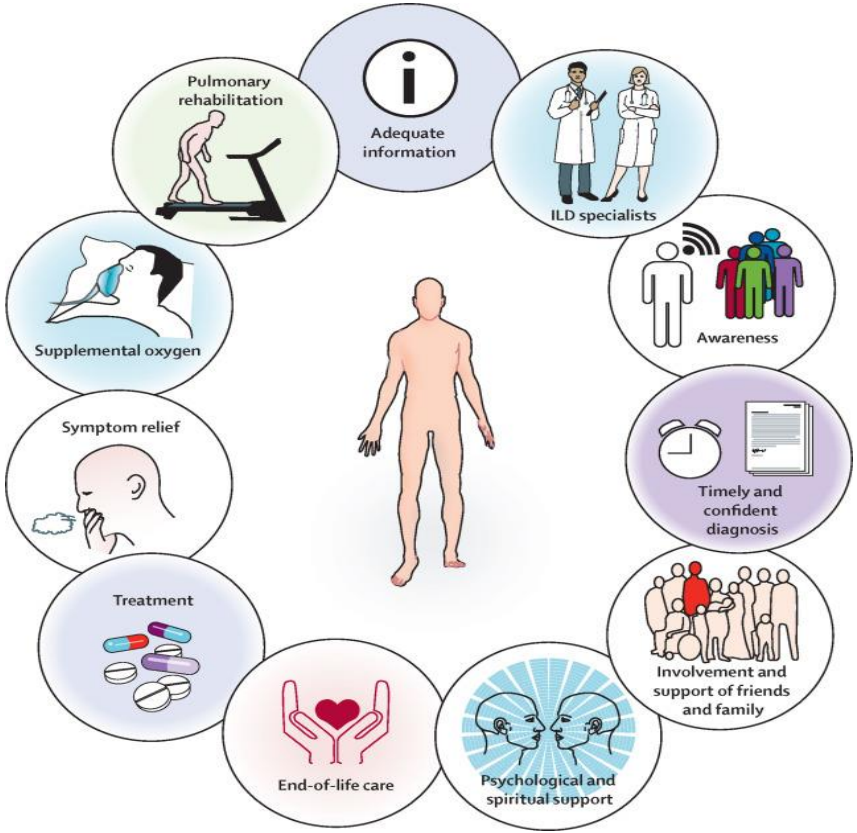

NOT ONLY FOR END OF LIFE. Image: Kreuter et al, 2017

Case

30-ish year old woman. Hx RA.
Rx: Pred 5mg + adalimumab.
GI s/e on MMF. Refused Rituximab

CC: shortness of breath

Exam: +Digital clubbing, insp. crackles
HRCT: Upper/mid lung predominant reticulation w/traction bronchiectasis, superimposed GGO.

CASE QUESTIONS

Is this RA-ILD?

How to I diagnose this?

How to manage?

How will she do over time?

CLOSING

- Pulmonary involvement is common in CTD
- Lung involvement does not parallel systemic disease
- ILD can be progressive, leading to significant morbidity and mortality
- Partner with your pulmonary team

REFERENCE

Aburto, M., Herráez, I., Iturbe, D., & Jiménez-Romero, A. (2018). Diagnosis of Idiopathic Pulmonary Fibrosis: Differential Diagnosis. *Medical sciences (Basel, Switzerland)*, *6*(3), 73. https://doi.org/10.3390/medsci6030073

Bendstrup E, Møller J, Kronborg-White S, Prior TS, Hyldgaard C. Interstitial Lung Disease in Rheumatoid Arthritis Remains a Challenge for Clinicians. J Clin Med. 2019 Nov 21;8(12):2038. doi: 10.3390/jcm8122038. PMID: 31766446; PMCID: PMC6947091

Brown K. K. (2007). Rheumatoid lung disease. *Proceedings of the American Thoracic Society*, *4*(5), 443–448. https://doi.org/10.1513/pats.200703-045MS

Chung WS, Peng CL, Lin CL, Chang YJ, Chen YF, Chiang JY, Sung FC, Kao CH. Rheumatoid arthritis increases the risk of deep vein thrombosis and pulmonary thromboembolism: a nationwide cohort study. Ann Rheum Dis. 2014 Oct;73(10):1774-80. doi: 10.1136/annrheumdis-2013-203380. Epub 2013 Aug 7. PMID: 23926057.

Cordier J. (2000). Organising pneumonia. *Thorax* 2000;**55:**318-328.

Cojocaru, M., Cojocaru, I. M., Silosi, I., & Vrabie, C. D. (2011). Pulmonary manifestations of systemic autoimmune diseases. *Maedica*, *6*(3), 224–229.

Dellaripa, P.F., Danoff, S.K. (2020). Interstitial Lung Disease in Dermatomyositis and Polymyositis: Treatment. In H.Hollingsworth and M.R. Curtis (Ed.) *UpToDate.* Retrieved on 11/18/2020. https://www.uptodate.com/contents/interstitial-lung-disease-in-dermatomyositis-and-polymyositis-treatment

REFERENCE

Fagan, K.A., King, T.E. (2020). Lymphoid Interstitial Pneumonia in Adults. In H. Hollingsworth (Ed.), *UpToDate.* Retrieved on 11/1/2020. https://www.uptodate.com/contents/lymphoid-interstitial-pneumonia-in-adults?search=lip&source=search_result&selectedTitle=1~150&usage_type=default&display_rank=1

Flaherty KR, Wells AU, Cottin V, Devaraj A, Walsh SLF, Inoue Y, Richeldi L, Kolb M, Tetzlaff K, Stowasser S, Coeck C, Clerisme-Beaty E, Rosenstock B, Quaresma M, Haeufel T, Goeldner RG, Schlenker-Herceg R, Brown KK; INBUILD Trial Investigators. Nintedanib in Progressive Fibrosing Interstitial Lung Diseases. N Engl J Med. 2019 Oct 31;381(18):1718-1727. doi: 10.1056/NEJMoa1908681. Epub 2019 Sep 29. PMID: 31566307.

Fischer A, du Bois R. Interstitial lung disease in connective tissue disorders. Lancet. 2012 Aug 18;380(9842):689-98. doi: 10.1016/S0140-6736(12)61079-4. Erratum in: Lancet. 2012 Sep 29;380(9848):1148. PMID: 22901890.

Fischer, A., Patel, N. M., & Volkmann, E. R. (2019). Interstitial Lung Disease in Systemic Sclerosis: Focus on Early Detection and Intervention. *Open access rheumatology : research and reviews*, *11*, 283–307. https://doi.org/10.2147/OARRR.S226695

Fragoulis, G. E., Nikiphorou, E., Larsen, J., Korsten, P., & Conway, R. (2019). Methotrexate-Associated Pneumonitis and Rheumatoid Arthritis-Interstitial Lung Disease: Current Concepts for the Diagnosis and Treatment. *Frontiers in medicine*, *6*, 238. https://doi.org/10.3389/fmed.2019.00238

REFERENCE

Goh NS, Desai SR, Veeraraghavan S, Hansell DM, Copley SJ, Maher TM, Corte TJ, Sander CR, Ratoff J, Devaraj A, Bozovic G, Denton CP, Black CM, du Bois RM, Wells AU. Interstitial lung disease in systemic sclerosis: a simple staging system. Am J Respir Crit Care Med. 2008 Jun 1;177(11):1248-54. doi: 10.1164/rccm.200706-877OC. Epub 2008 Mar 27. PMID: 18369202.

Juge PA, Lee JS, Lau J, Kawano-Dourado L, Rojas Serrano J, Sebastiani M, Koduri G, Matteson E, Bonfiglioli K, Sawamura M, Kairalla R, Cavagna L, Bozzalla Cassione E, Manfredi A, Mejia M, Rodríguez-Henriquez P, González-Pérez MI, Falfán-Valencia R, Buendia-Roldán I, Pérez-Rubio G, Ebstein E, Gazal S, Borie R, Ottaviani S, Kannengiesser C, Wallaert B, Uzunhan Y, Nunes H, Valeyre D, Saidenberg-Kermanac'h N, Boissier MC, Wemeau-Stervinou L, Flipo RM, Marchand-Adam S, Richette P, Allanore Y, Dromer C, Truchetet ME, Richez C, Schaeverbeke T, Lioté H, Thabut G, Deane KD, Solomon J, Doyle T, Ryu JH, Rosas I, Holers VM, Boileau C, Debray MP, Porcher R, Schwartz DA, Vassallo R, Crestani B, Dieudé P. Methotrexate and rheumatoid arthritis associated interstitial lung disease. Eur Respir J. 2020 Jul 9:2000337. doi: 10.1183/13993003.00337-2020. Epub ahead of print. PMID: 32646919.

Kim, S. C., Schneeweiss, S., Liu, J., & Solomon, D. H. (2013). Risk of venous thromboembolism in patients with rheumatoid arthritis. *Arthritis care & research*, *65*(10), 1600–1607. https://doi.org/10.1002/acr.22039

King, T.Ed. (2020). Overview of bronchiolar disorders in adults. In H.Hollingsworth (Ed.), *UpToDate.* Retrieved on 11/1/2020. https://www.uptodate.com/contents/overview-of-bronchiolar-disorders-in-adults?search=bronchiolitis%20obliterans&source=search_result&selectedTitle=1~150&usage_type=default&display_rank=1

Kreuter M, Bendstrup E, Russell AM, Bajwah S, Lindell K, Adir Y, Brown CE, Calligaro G, Cassidy N, Corte TJ, Geissler K, Hassan AA, Johannson KA, Kairalla R, Kolb M, Kondoh Y, Quadrelli S, Swigris J, Udwadia Z, Wells A, Wijsenbeek M. Palliative care in interstitial lung disease: living well. Lancet Respir Med. 2017 Dec;5(12):968-980. doi: 10.1016/S2213-2600(17)30383-1. Epub 2017 Oct 13. PMID: 29033267.

REFERENCE

Nayfeh AS, Chippa V, Moore DR. Nonspecific Interstitial Pneumonitis. [Updated 2020 Sep 8]. In: StatPearls [Internet]. Treasure Island (FL): StatPearls Publishing; 2020 Jan-. Available from: https://www.ncbi.nlm.nih.gov/books/NBK518974/

Panagiotidou, E., Sourla, E., Kotoulas, S. X., Akritidou, S., Bikos, V., Bagalas, V., Stanopoulos, I., & Pitsiou, G. (2017). Rheumatoid arthritis associated pulmonary hypertension: Clinical challenges reflecting the diversity of pathophysiology. *Respiratory medicine case reports*, *20*, 164–167. https://doi.org/10.1016/j.rmcr.2017.02.006

Ryerson, Christopher J.a; Collard, Harold R.b Update on the diagnosis and classification of ILD, Current Opinion in Pulmonary Medicine: September 2013 - Volume 19 - Issue 5 - p 453-459. doi: 10.1097/MCP.0b013e328363f48d

Schwaiblmair, M., Behr, W., Haeckel, T., Märkl, B., Foerg, W., & Berghaus, T. (2012). Drug induced interstitial lung disease. *The open respiratory medicine journal*, *6*, 63–74. https://doi.org/10.2174/1874306401206010063

Simon, T. A., Thompson, A., Gandhi, K. K., Hochberg, M. C., & Suissa, S. (2015). Incidence of malignancy in adult patients with rheumatoid arthritis: a meta-analysis. *Arthritis research & therapy*, *17*(1), 212. https://doi.org/10.1186/s13075-015-0728-9

Singh R, Huang W, Menon Y, Espinoza LR. Shrinking lung syndrome in systemic lupus erythematosus and Sjogren's syndrome. J Clin Rheumatol. 2002 Dec;8(6):340-5. doi: 10.1097/00124743-200212000-00011. PMID: 17041405.

Stojan, G., Baer, A. N., & Danoff, S. K. (2013). Pulmonary manifestations of Sjögren's syndrome. *Current allergy and asthma reports*, *13*(4), 354–360. https://doi.org/10.1007/s11882-013-0357-9

REFERENCE

Swigris JJ, Fischer A, Gillis J, Meehan RT, Brown KK. Pulmonary and thrombotic manifestations of systemic lupus erythematosus. Chest. 2008 Jan;133(1):271-80. doi: 10.1378/chest.07-0079. Erratum in: Chest. 2008 Mar;133(3):832. Gilles, Joann [corrected to Gillis, Joann]. PMID: 18187752.

Takano, A.M, Fukuoka, J., Leslie, K.O. (2018). Histopathology of Interstitial Lung Disease: A Pattern Based Approach. In M. Thillai, D.R. Moller, and K.C. Meyer, *Clinical Handbook of Interstitial Lung Disease*, pp 11-37. CRC Press

Vacchi, C., Sebastiani, M., Cassone, G., Cerri, S., Della Casa, G., Salvarani, C., & Manfredi, A. (2020). Therapeutic Options for the Treatment of Interstitial Lung Disease Related to Connective Tissue Diseases. A Narrative Review. *Journal of clinical medicine*, *9*(2), 407. https://doi.org/10.3390/jcm9020407