RhAPP

RHEUMATOLOGY ADVANCED PRACTICE PROVIDERS

RHAPP NATIONAL CONFERENCE

SEPTEMBER 8-10, 2022

Introduction to Salivary Gland Ultrasound

Nate Mathews, RMSK
KyleGeorge, PA-C
McKenna Syphus, RMA

Disclosure Policy

All individuals in control of the content of continuing education activities provided by the Annenberg Center for Health Sciences at Eisenhower (ACHS) are required to disclose to the audience all relevant financial relationships related to the content of the presentation or enduring material. Full disclosure of all relevant financial relationships will be made in writing to the audience prior to the activity. All other staff at the Annenberg Center for Health Sciences at Eisenhower and RhAPP have no relationships to disclose.

Faculty Disclosure

- There are no financial relationships to disclose.

Faculty Disclosures

- None



BORING!!!

The Glands



Plate 21A

Facial Nerve Branches and Parotid Gland in Situ

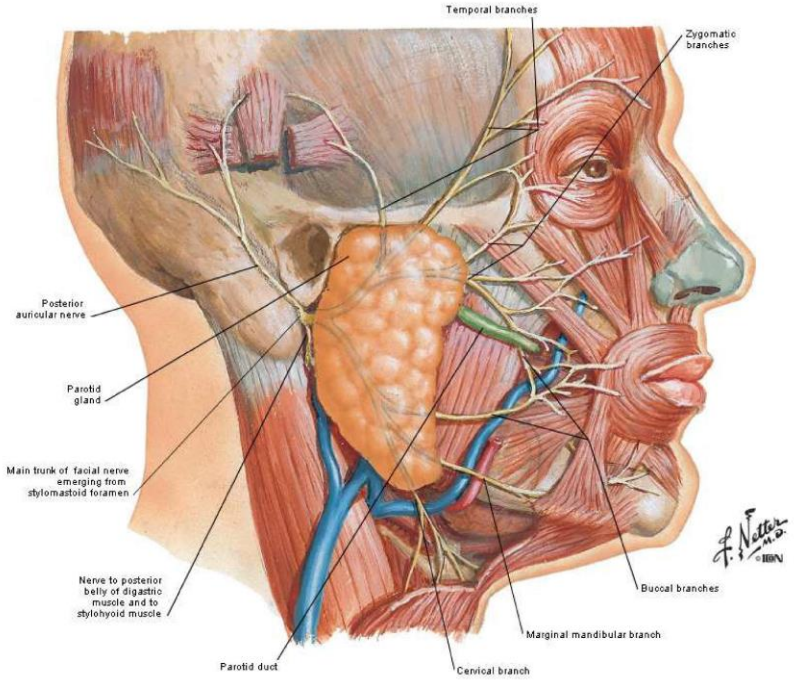

Plate 57A

Salivary Glands
Dissection

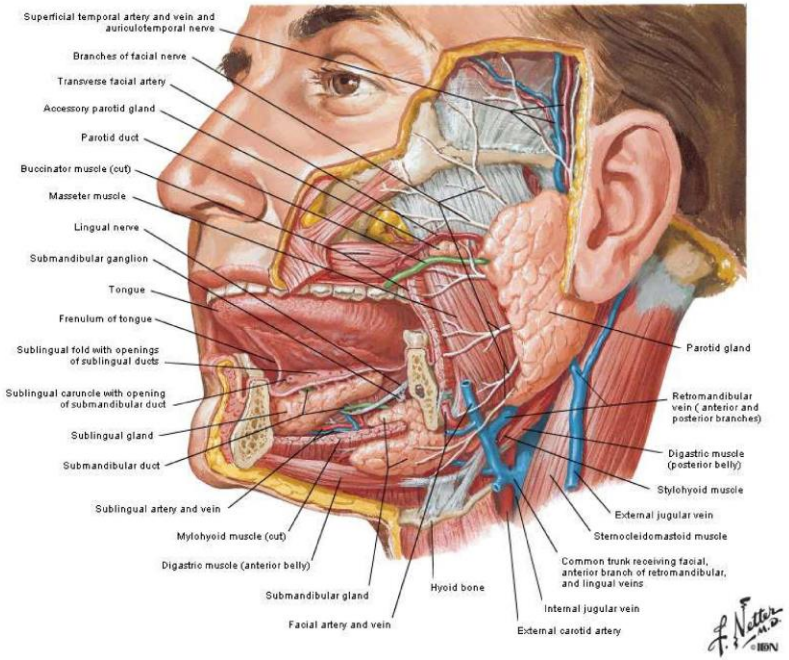

Indications

- Lump in the gland/neck
- Pain in cheek, posterior jaw & neck
- Dry mouth
- Abnormality on previous x-ray, CT, or MRI

Imaging Technique

- Linear array transducer
- Superficial location
  - Highest megahertz possible
- Power Doppler
  - Mass evaluation, inflammatory process
- Bilateral examination
- Preferably NPO≈30 min. prior to examination

Parotid gland

- Located in retromandibular fossa
- Anterior to ear and sternocleidomastoid muscle
- Covers posterior mandible/masseter muscle
- Facial nerves divide superficial/deep lobe
  - Not usually visible with US
  - Adjacent to retromandibular vein
- Homogeneously echogenic (fat content)
- Benign intraglandular nodes common

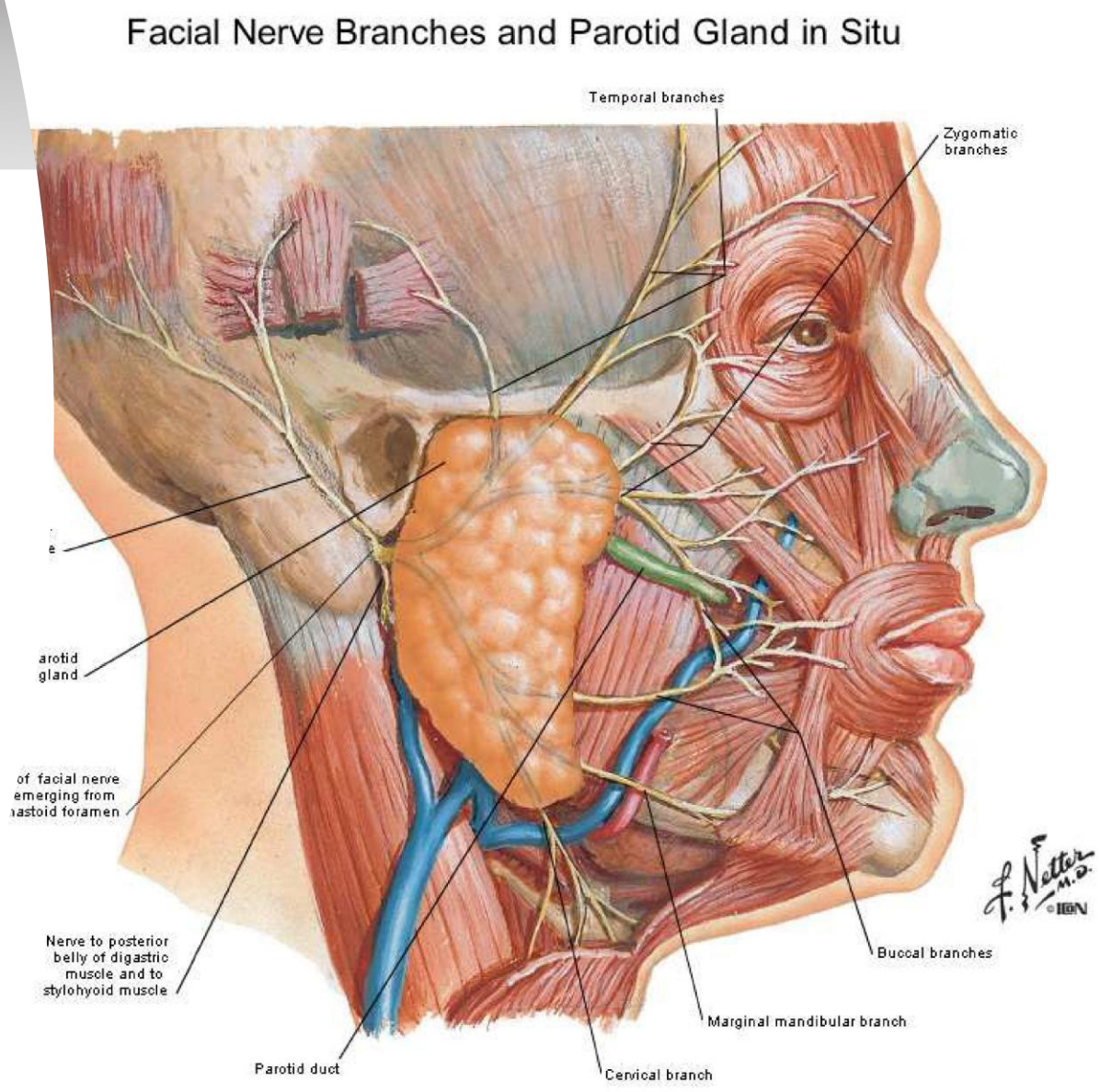

Parotid Salivary Gland

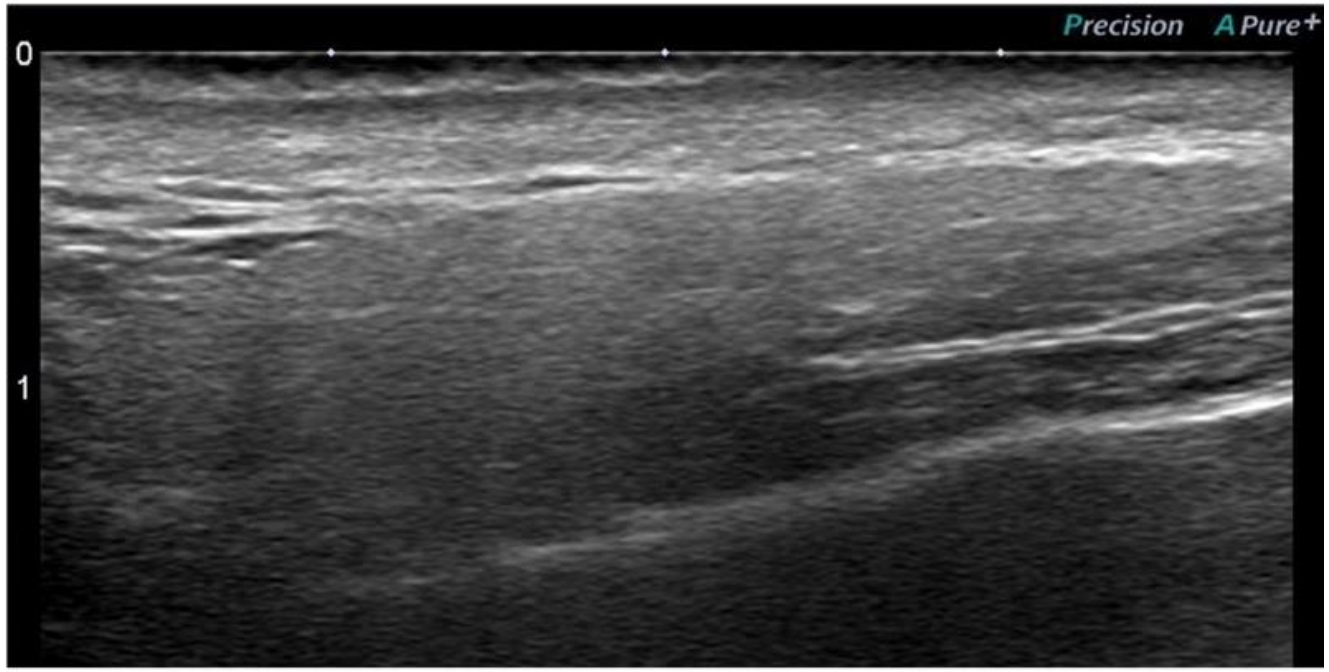

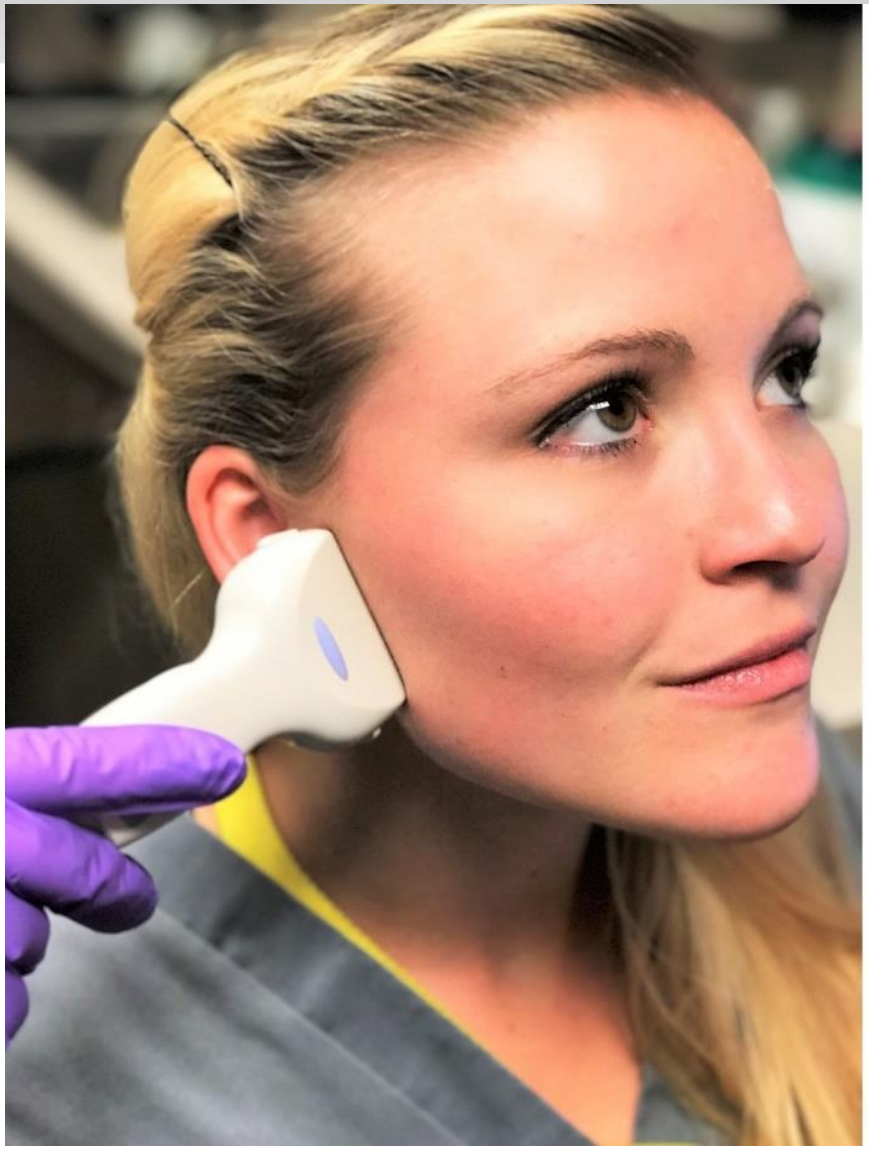

Submandibular Gland

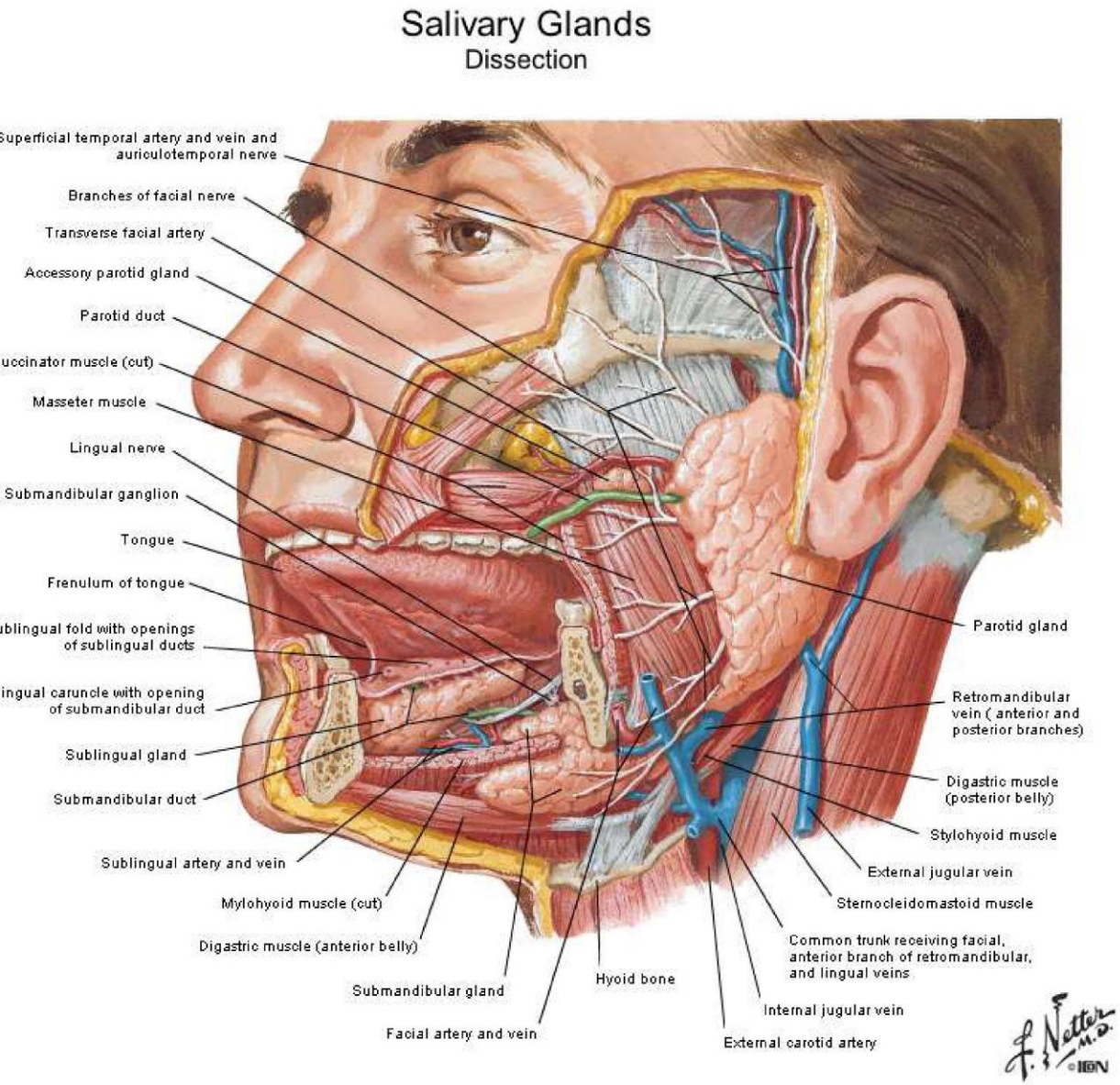

- located in posterior submandibular triangle
  - Borders = anterior/posterior bellies of the digastric muscle & mandible.
- Anteriorly = connective tissue & lymph nodes (US differentiates node vs. gland)
- Posteriorly, gland bordered by mylohyoid and hyoglossus muscles.
- Tubular structures = Wharton's duct vs. facial artery (power Doppler)

Submandibular Salivary Gland

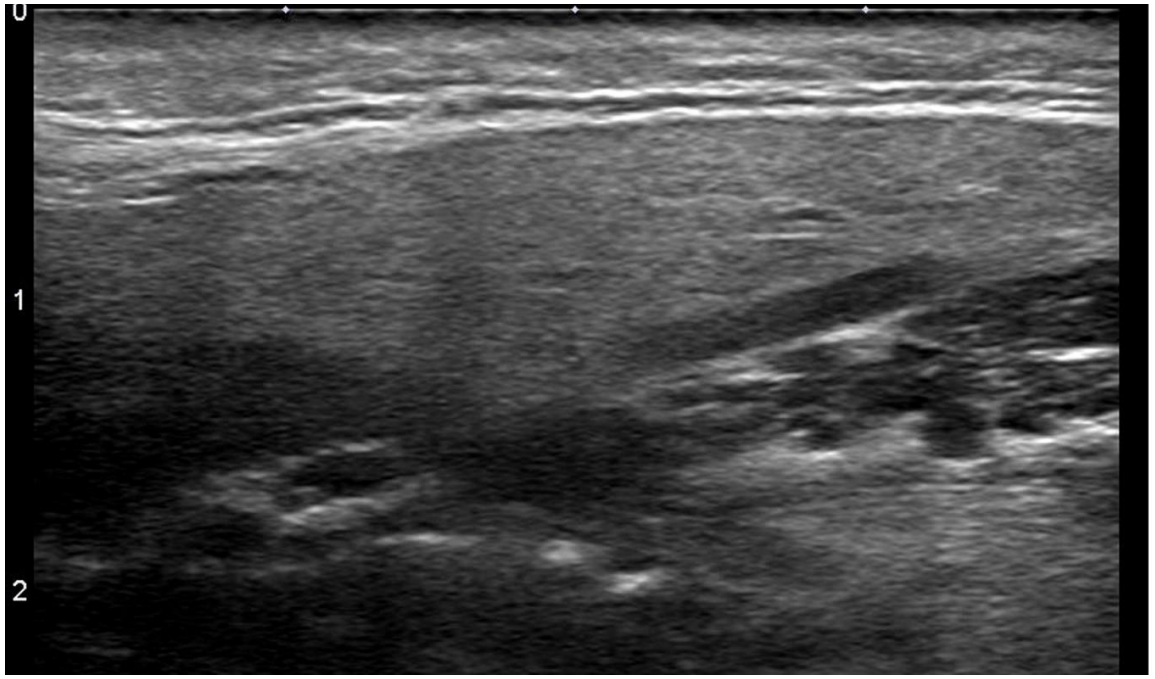

Inflammatory Process: Acute

- Most common salivary gland pathology
- painful, swollen, often bilateral
- Viral in children–mumps, CMV
- Bacterial in adults–staph aureus, oral flora
- US–Elarged, Hypoechoic, Hypervascular
- Associated lymphadenopathy
- Complication = intraglandular abscess

Sjogren's Syndrome

- Chronic lymphocytic/plasma cell infiltration
- Destruction of salivary & lacrimal glands
- Dry eyes/mouth
- Females > 40 years
- Associated with lymphoproliferative disease
- US screening for lymphomatous masses
- FNA for lesions > 2 cm
- US = inhomogenous multiple hypoechoic nodules

Pathology

Salivary Gland Grading

De Vita Et. Al. OMERACT

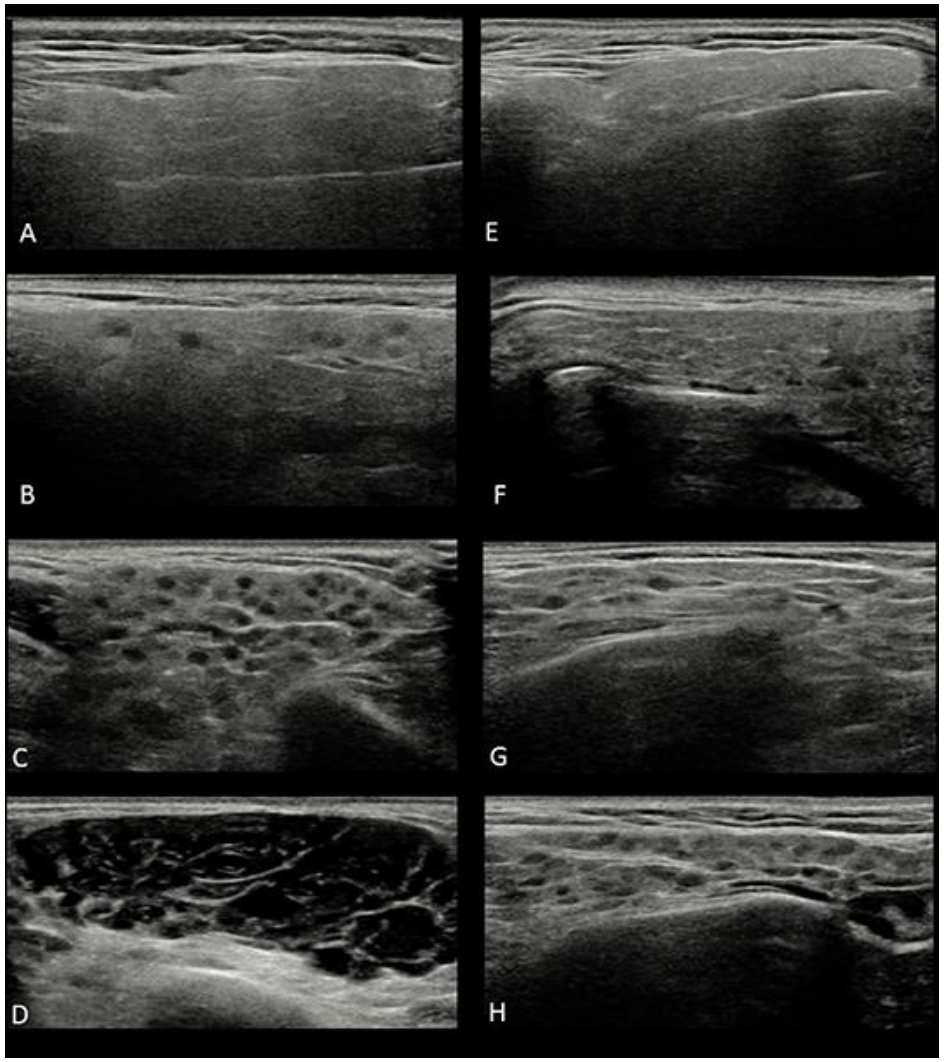

Ultrasound images of parotid glands in the two four-grade semi-quantitative scoring system: (A) De Vita et al. score grade 0; (B) De Vita et al. score grade 1; (C) De Vita et al. score grade 2; (D) De Vita et al. score grade 3; (E) OMERACT score grade 0; (F) OMERACT score grade 1; (G) OMERACT score grade 2; (H) OMERACT score grade 3

Salivary Gland Parenchymal Heterogeneity and Hyperemia

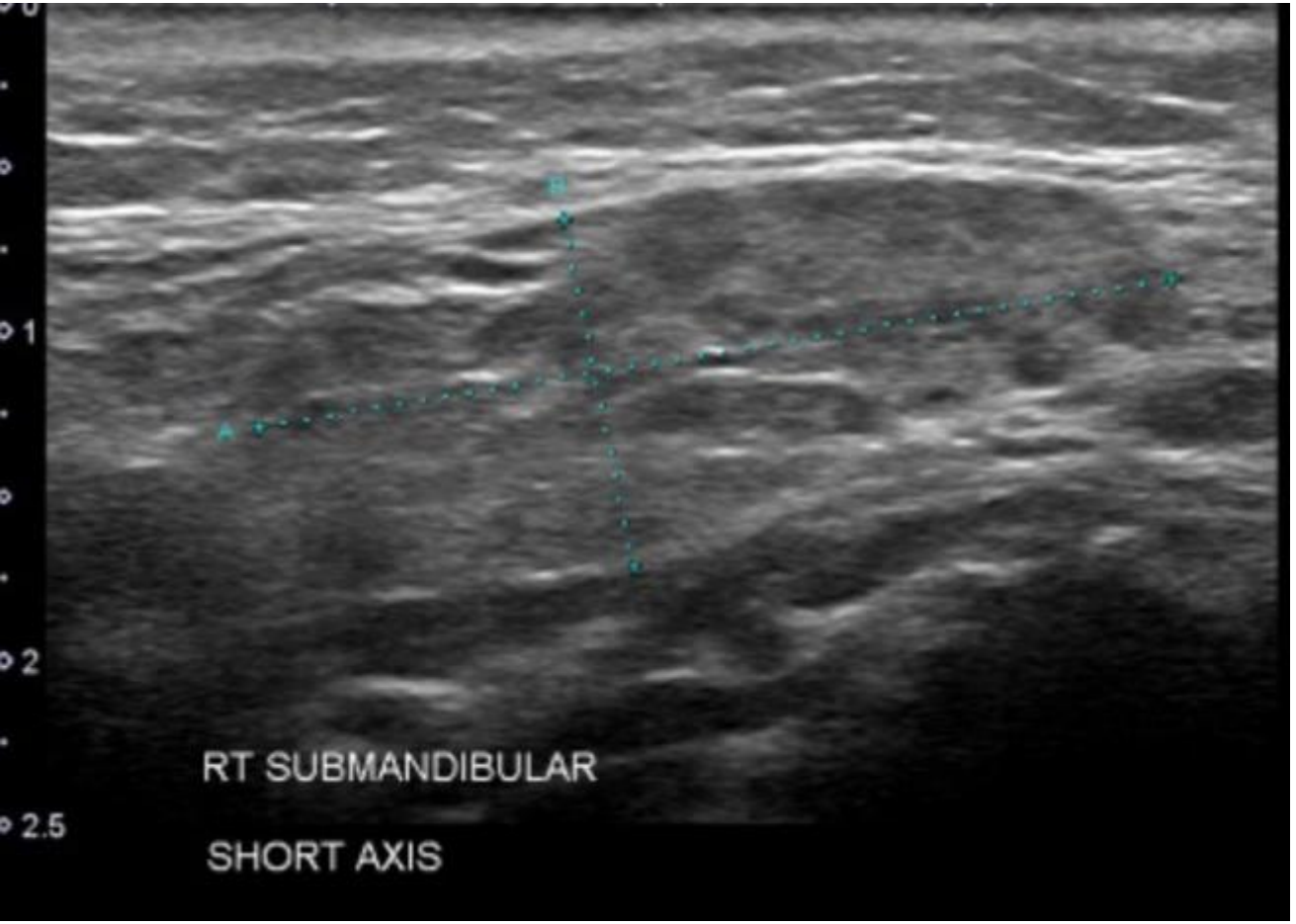

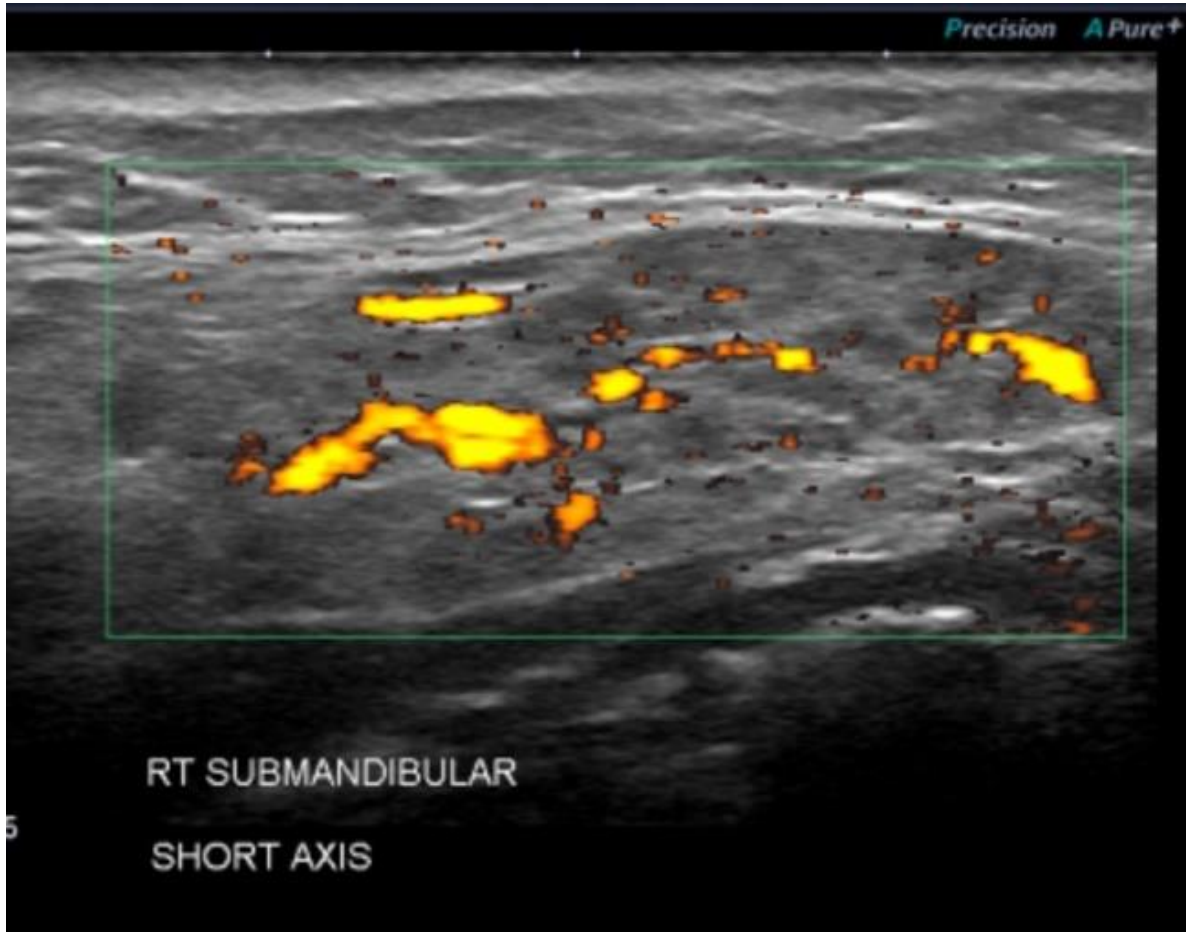

Chronic parotitis with an inhomogeneous right parotid gland

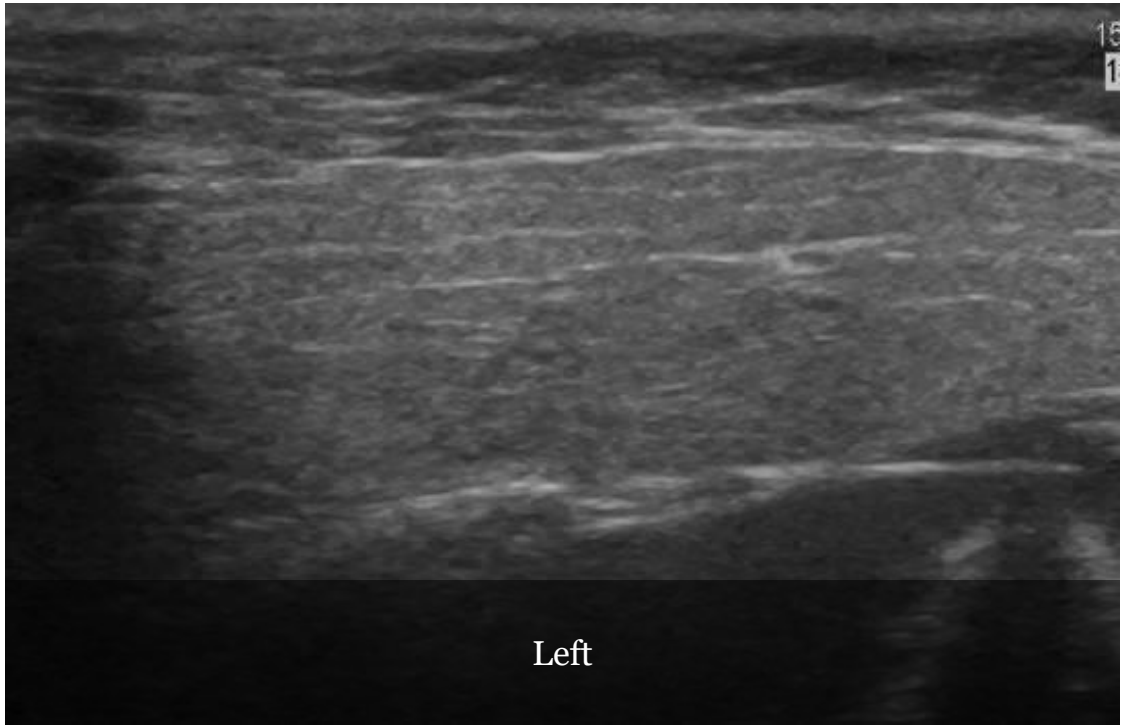

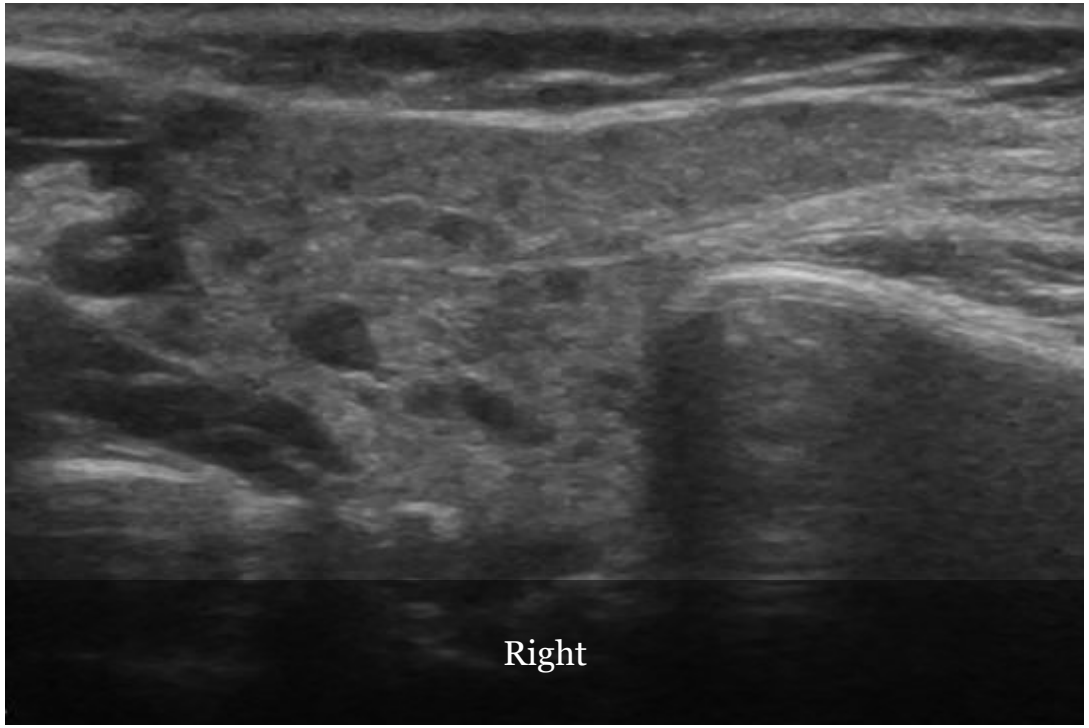

Inhomogeneous salivary glands in a patient with Sjögren's disease (Grade 2)

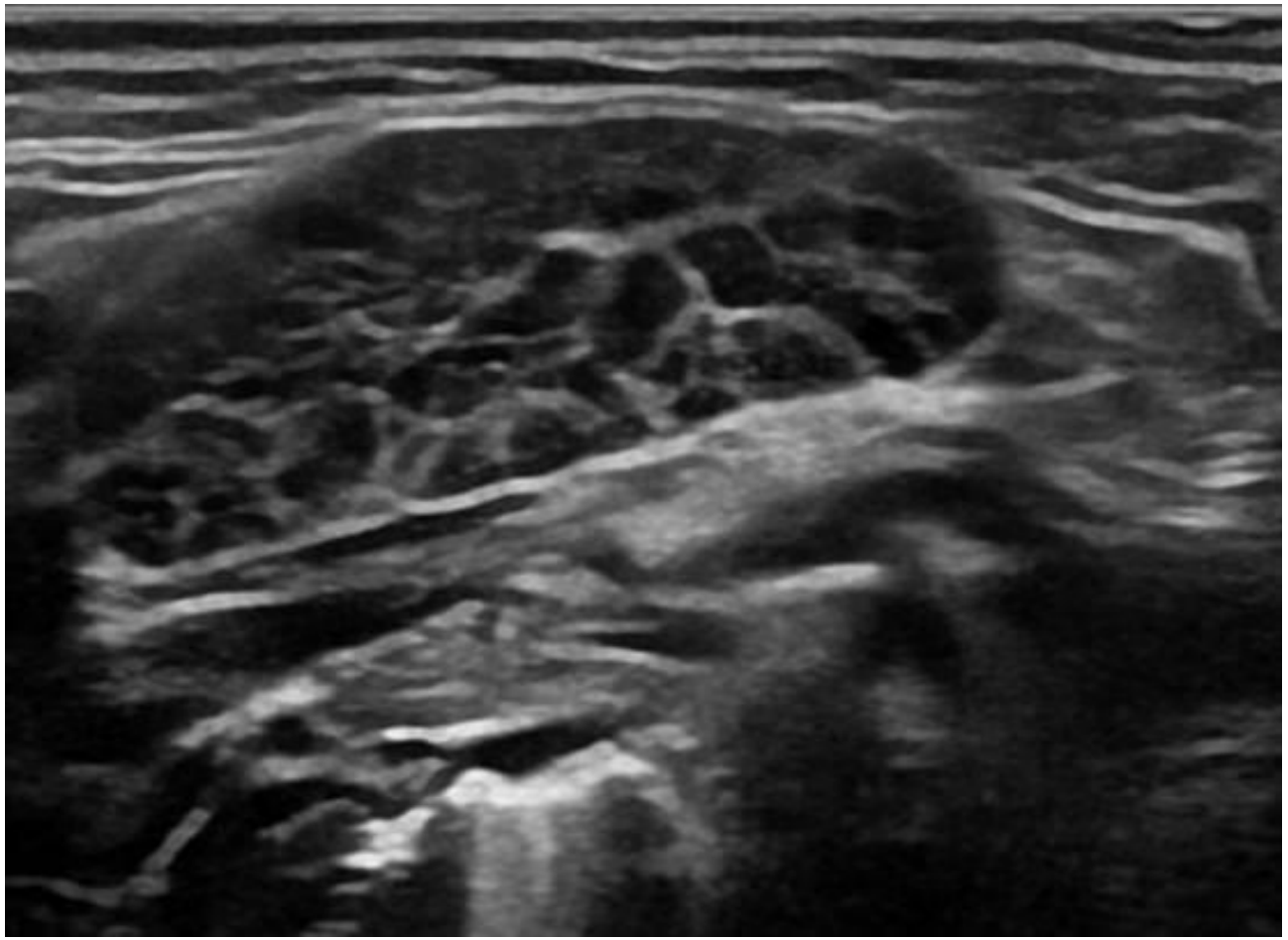

Cystic lesions within the Parotid Gland

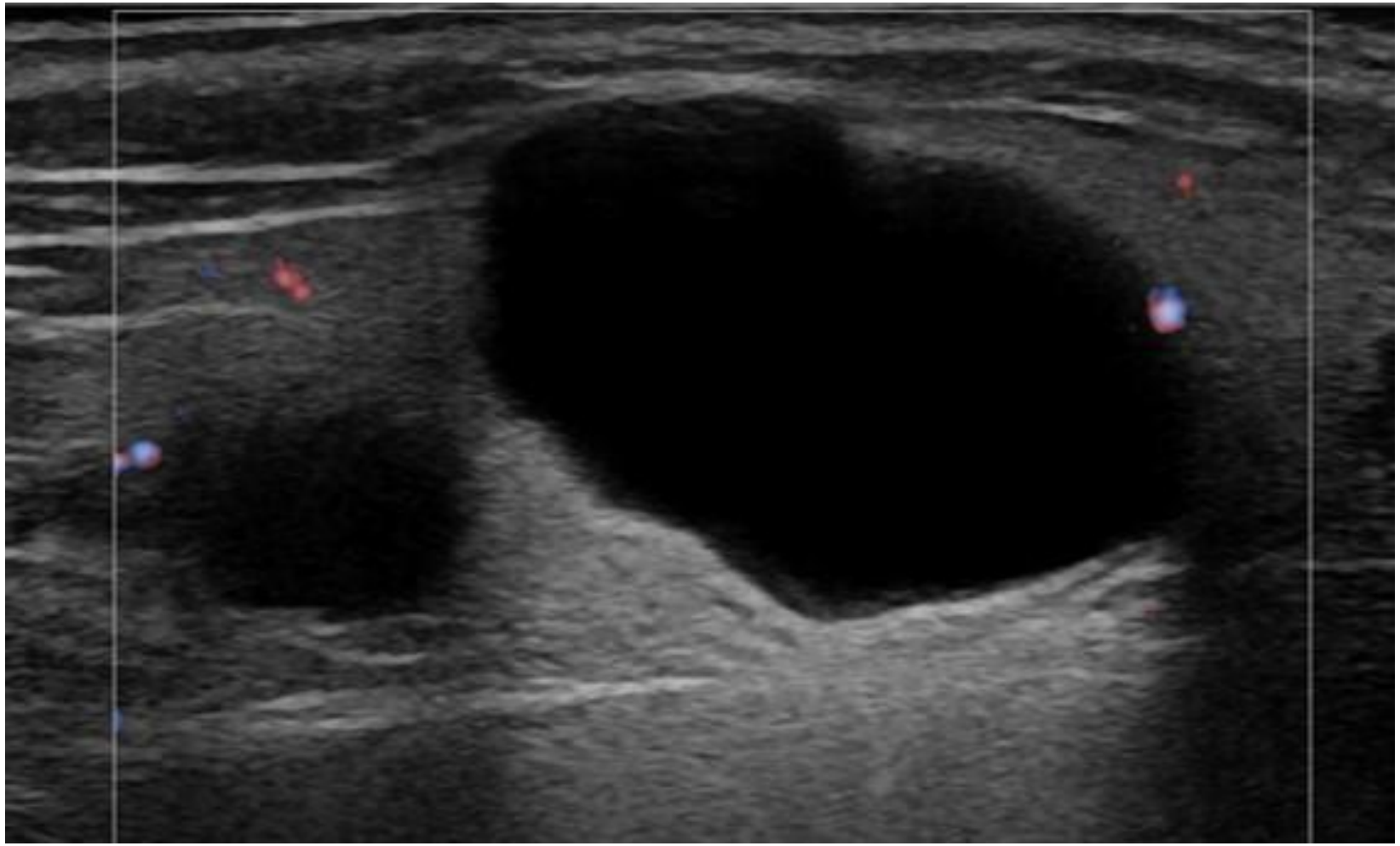

Grade 1 Heterogeneity & Hyperemia

Submandibular Calculus (Stone)

Sample ICD-10 Codes

Diagnosis	Description
M3500	Sjogren syndrome
H16229	Sicca Syndrome
H16223	Keratoconjunct sicca, not specified as Sjogren's, bilateral

Sample Salivary Gland Report Template

LOCATION: Bilateral Salivary glands (Parotids and Submandibular glands)

HISTORY: Patient presents with dry mouth / sicca symptoms / Sjogren's syndrome.

Evaluate for hyperemia / parenchymal damage

EXAMINATION: Performed high-resolution musculoskeletal ultrasound of bilateral salivary glands (views of parotid and submandibular glands) with Power Doppler

- **IMPRESSION:**
- RIGHT**:**

- Parotid: Grade [default value]
- Submandibular: Grade [default value]

- LEFT**:**

- Parotid: Grade [default value]
- Submandibular: Grade [default value]

- **CONCLUSION:**
- [default value]

Salivary gland grading:

Grade 0 - normal homogenous parenchyma

Grade 1 - mild parenchymal heterogeneity

Grade 2 - evident parenchymal heterogeneity

Conclusion

- Salivary gland ultrasound is emerging as a good method for objectively evaluating Sicca syndrome.
- Ultrasound detected parenchymal heterogeneity appears to be a good sign for identifying primary Sjogren's syndrome.
- Color & power Doppler enable assessment of gland inflammation, which can be useful in determining if symptoms arise as reaction to medication (i.e. pain medication), or due to inflammatory disease.

Questions/Concerns