RhAPP

RHEUMATOLOGY ADVANCED PRACTICE PROVIDERS

RHAPP NATIONAL CONFERENCE

SEPTEMBER 8-10, 2022

Injection Workshop

Kris Giani, PA-C
Andrea Mace, PA-C
Jennifer Simpson, DNP

Disclosure Policy

All individuals in control of the content of continuing education activities provided by the Annenberg Center for Health Sciences at Eisenhower (ACHS) are required to disclose to the audience all relevant financial relationships related to the content of the presentation or enduring material. Full disclosure of all relevant financial relationships will be made in writing to the audience prior to the activity. All other staff at the Annenberg Center for Health Sciences at Eisenhower and RhAPP have no relationships to disclose.

Faculty Disclosures

- Kris Giani, PA-C-None
- Andrea Mace, PA-C- None
- Jennifer Simpson, DNP- None

Basic Joints to Be Discussed

- Hip – Greater Trochanteric bursitis
- Shoulder Joint
- Knee joint

Injection Preparation

Clean technique

- Betadine swab/chlorhexidine swab
- Alcohol pad
- Band aid
- Syringe with medication and appropriate sized needle
- Ethyl chloride spray or local anesthetic
- Gauze
- Gloves
- Hemostat – if aspirating

Needle Sizes

- Large joint: 22 gauge or 25 gauge x 1.5 inches in length
- Medium joint: 25 gauge x 1.5 inches in length
- Small joint: 25 gauge x 1 inch or ½ inch in length
- Aspirations: 18 gauge x 1.5 inches

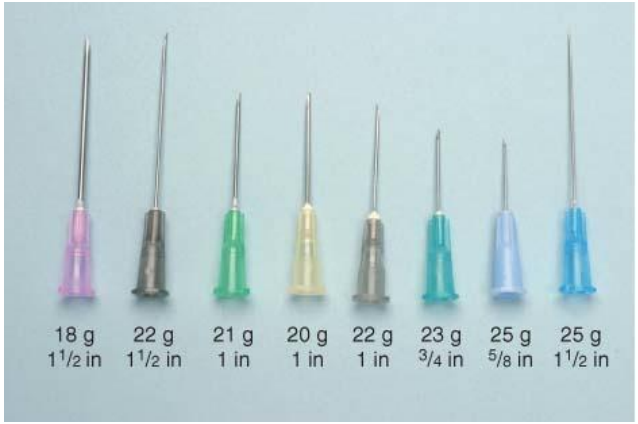

Corticosteroid Medications

Medication Name	Strength	Dose-Large	Dose-medium	Dose- small
Kenalog-40 (triamcinolone)	40mg/mL	80mg or 2mL	40mg or 1mL	20mg 0.5mL
Celestone (betamethasone)	6mg/mL	24mg or 4mL	12mg or 2mL	3-6mg or 0.5-1mL
Depo-Medrol (methylprednisolone)	40mg/mL	80mg or 2mL	40mg or 2mL	20mg or 1mL
Decadron (dexamethasone)	4mg/mL	4mg or 1mL	2mg or 0.5mL	0.8-1mg or ~0.25mL
Zilretta (triamcinolone) Long acting)	32mg/5mL	32mg or 5mL- indicated for knees only	Not indicated	Not indicated

Trochanteric Bursa Injection

Hip Bursa Anatomy

- The trochanteric bursa is located over the lateral prominence of the greater trochanter of the femur. Trochanteric bursitis is confirmed by palpation of tenderness, and occasionally swelling over this bursal region
- Can be precipitated by repeated pressure or trauma to the area
- Contributing factors – osteoarthritis, rheumatoid arthritis, obesity and leg-length discrepancies

Indication for Injection

- Confirmed trochanteric bursitis which has been resistant to conservative treatments (i.e. ice, heat, topical and/or oral NSAIDs,
  physical therapy)

Trochanteric Bursa Injection (con’t)

Patient Positioning

- Patient should be positioned supine, lying laterally on opposite hip of the affected side

Landmark Palpation

- Identify the greater trochanter by palpating the femur from the mid-shaft proximally until the area of bony protrusion is reached
- The injection site is the point of maximal tenderness or swelling

Pharmaceutical/Equipment Choice

- Syringe: 5 to 10 mL
- Needle: 22 or 25 gauge 1.5 inch
- Corticosteroid: 40-80 mg of methylprednisolone or triamcinolone
- Anesthetic: 1:1 ratio of Lidocaine to Corticosteroid
- Ethyl Chloride can be used as option topical anesthetic
- Area should be cleaned using sterile technique

Trochanteric Bursa Injection (con’t)

- Approach: Needle should be inserted at 90 degree angle to skin at the area of most tenderness until resistance is met by bone or needle is fully inserted. If resistance is met, needle should be withdrawn very slightly (2-3 mm), aspirate and then inject full amount of syringe

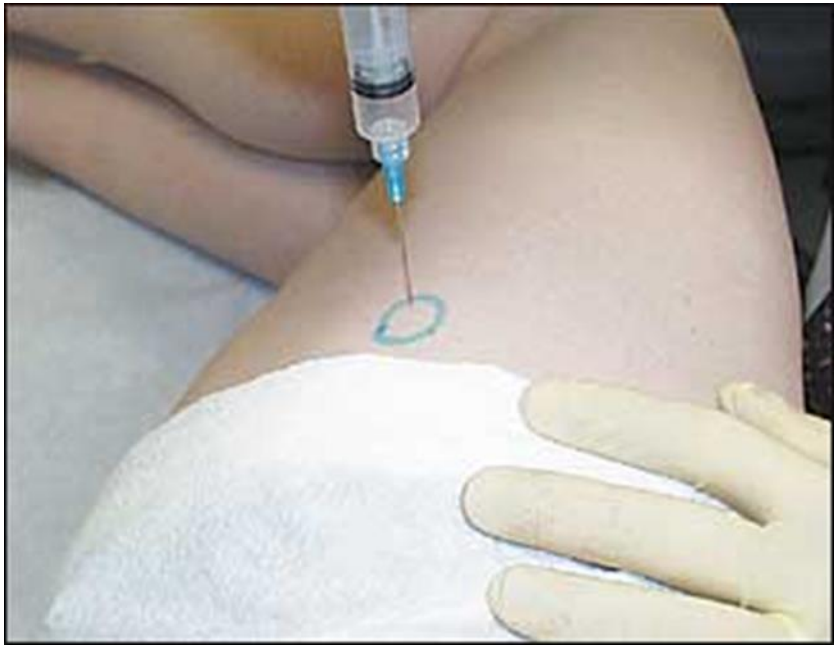

Shoulder Anatomy

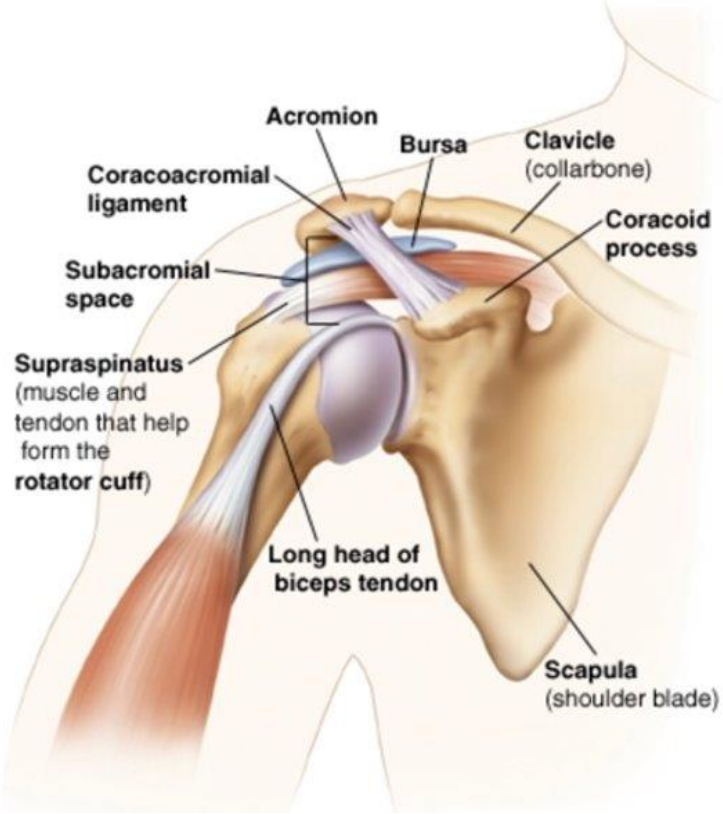

Shoulder Injection Indications

- **Primary arthritis of the glenohumeral joint**
- **Subacromial bursitis**
- **Acromioclavicular arthritis**
- **Rotator cuff tendonitis**
- **Impingement syndrome**
- **Adhesive capsulitis**

Positioning of Patient

- Positioning: Patient sitting on the exam table in a gown with access to the posterior, lateral and anterior shoulder. Provider position will depend on approach for the injection.
  - Posterior: stand behind the patient
  - Lateral: stand posterior/lateral to the patient
  - Anterior: stand in front of the patient

- Equipment:
  - Syringe: 5-10mL
  - Needle: 22 gauge 1.5 inches in length
  - Anesthetic: Lidocaine or Ethyl chloride spray

Shoulder Arthritis on X-rays

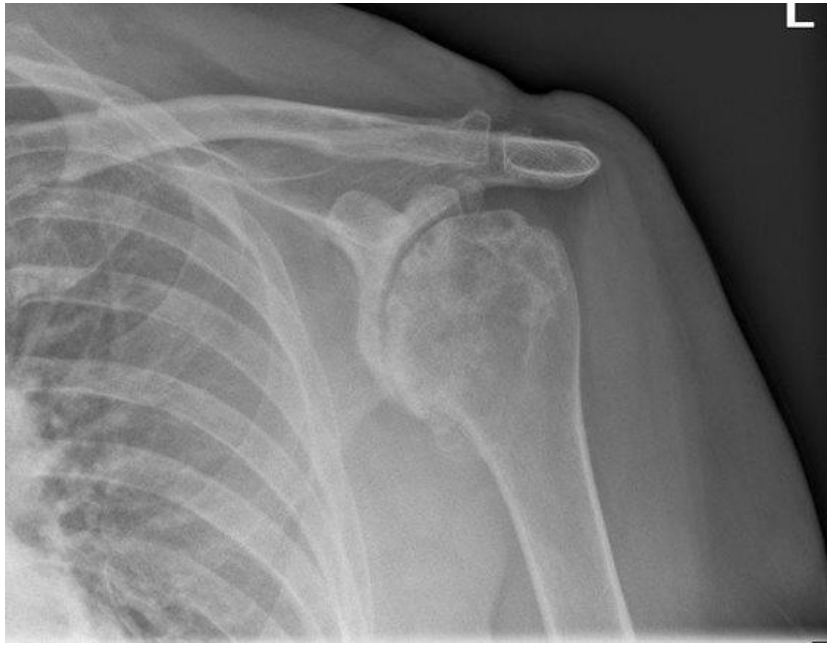

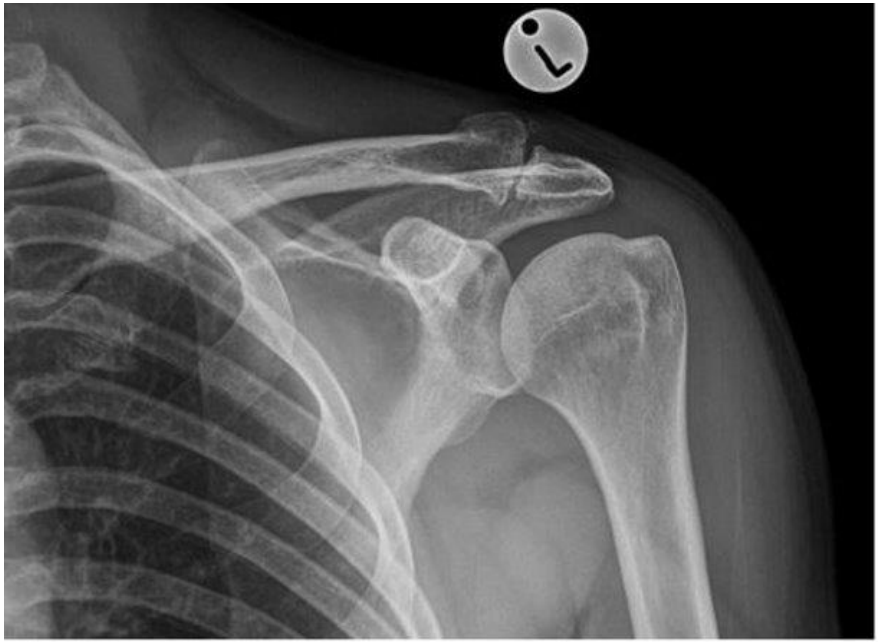

Posterior Approach – Shoulder

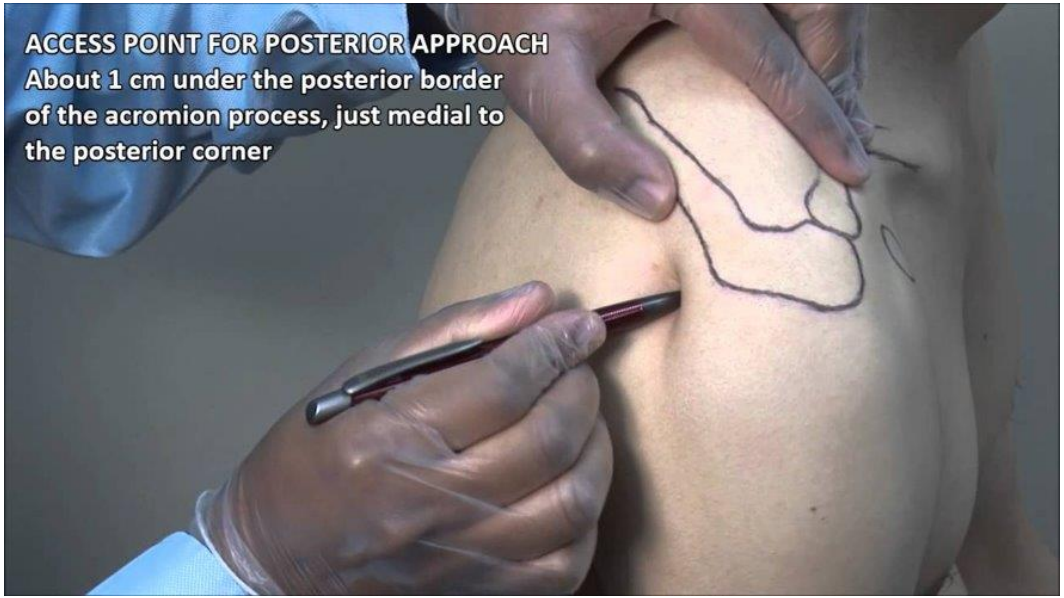

- Subacromial bursa-angle about 45 degrees up
- Glenohumeral joint-angled 90 degrees or perpendicular to the shoulder

Lateral Approach – Shoulder

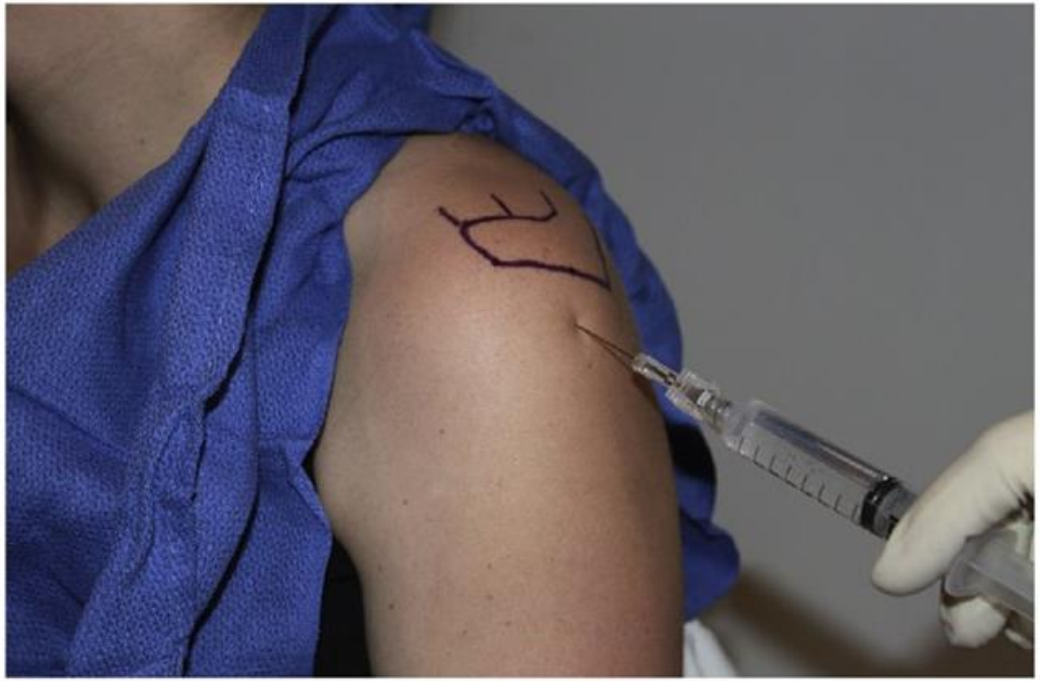

Fig. 5. Subacromial bursa injection with lateral approach.

Shoulder- Ultrasound

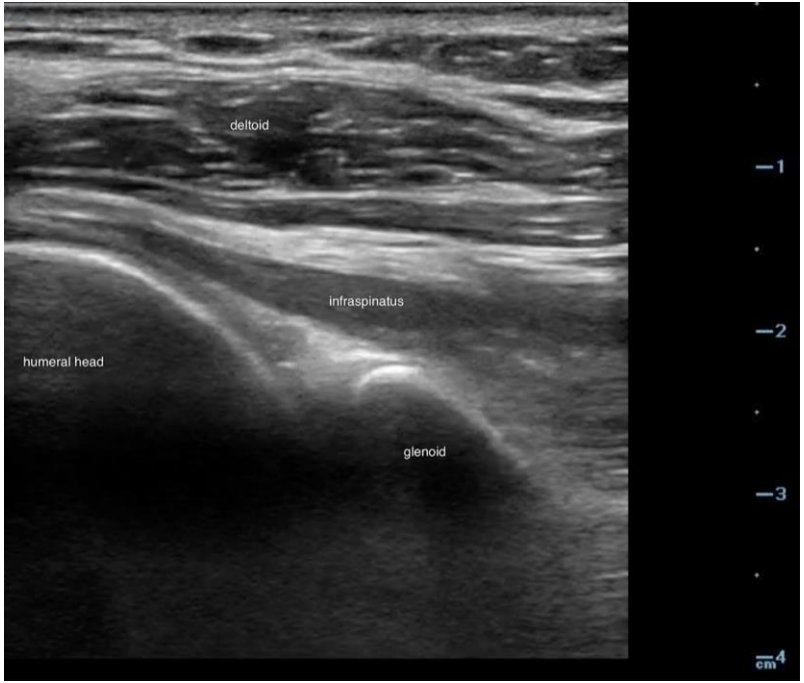

Knee Anatomy

- Two functional joints – the femoral-tibial and the femoral-patellar

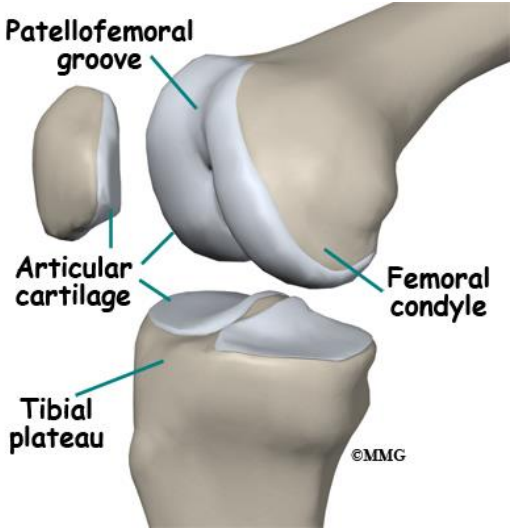

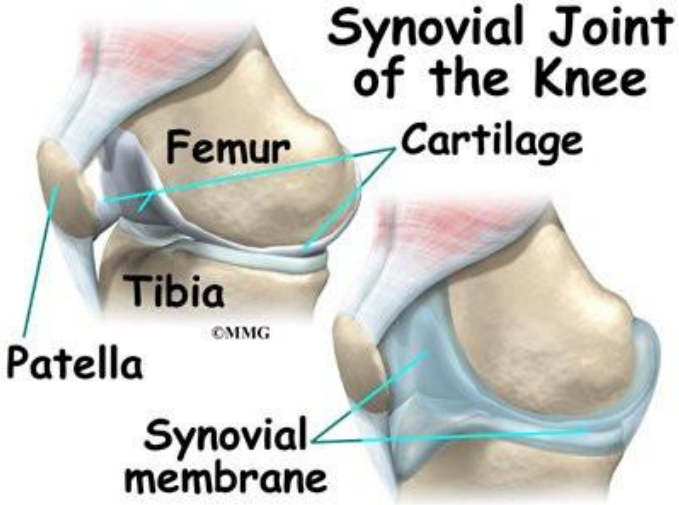

Knee- Indications for Injection/Aspiration

- Relieve discomfort associated with effusion
- Aid in diagnosis of unexplained effusion (rule out septic arthritis, should be performed immediately if suspected i.e. monoarticular red, hot swollen joint)
- Corticosteroids for advanced osteoarthritis or other noninfectious inflammatory arthropathies such as RA, gout or CPPD
- Visco-supplementation used to treat the pain of knee osteoarthritis

Intra-articular Knee Injection (con’t)

Patient Positioning

- For aspiration patient should be supine with the knee slightly flexed with posterior support
- For injection can be supine or seated with legs at 90 degrees dangling from exam table

Landmark Palpation

- Knee joint can be accessed medially, laterally or anteriorly. Choice is provider preference but lateral is most common. Begin by palpating all borders of the patella, needle insertion should at the deepest groove

Pharmaceutical/Equipment Choice

- Syringe: 5 to 10 mL for injection, 20 mL or larger for aspiration
- Needle: 22 gauge 1.5 inch for injection, 18-20 gauge for aspiration
- Corticosteroid: 40-80 mg of methylprednisolone or triamcinolone
- Anesthetic: 1:1 ratio of Lidocaine to Corticosteroid
- Ethyl Chloride can be used as option topical anesthetic
- Area should be cleaned using sterile technique

Approach: In the anterior approach, the knee is flexed 60 to 90 degrees, and the needle is inserted just lateral to the patellar tendon and parallel to the tibial plateau. In seated position, needle is inserted into the soft tissue between the patella and femur directed at a 45-degree angle aiming behind the patella to the middle of the joint. For aspiration, injection 1-2 mL Lidocaine and aspirate until no longer able, then inject corticosteroid.

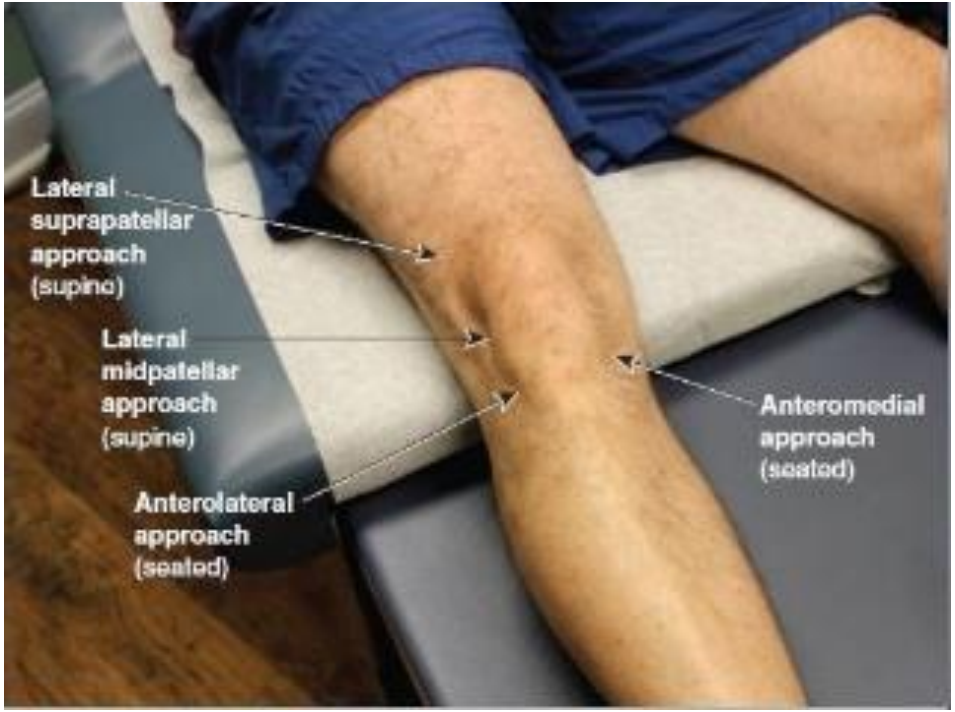
Lateral suprapatellar approach (supine)
Lateral midpatellar approach (supine)
Anterolateral approach (seated)
Anteromedial approach (seated)

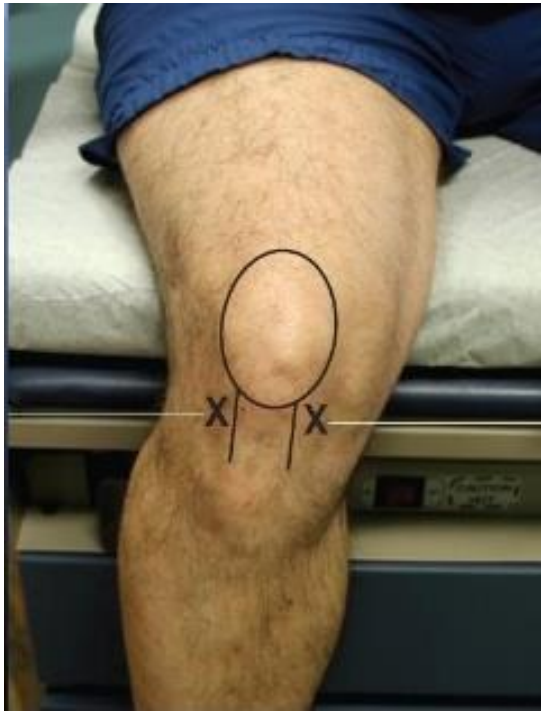
X
X

Knee- Ultrasound

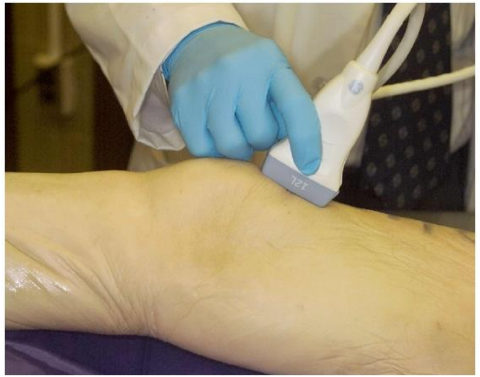

(a)

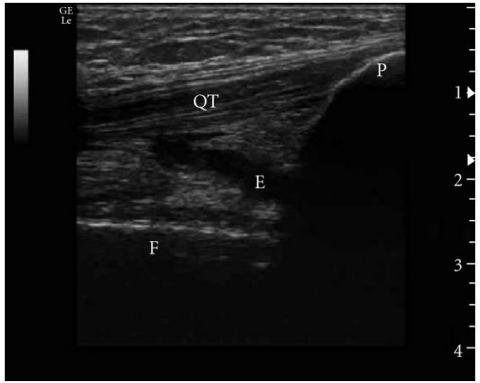

(b)

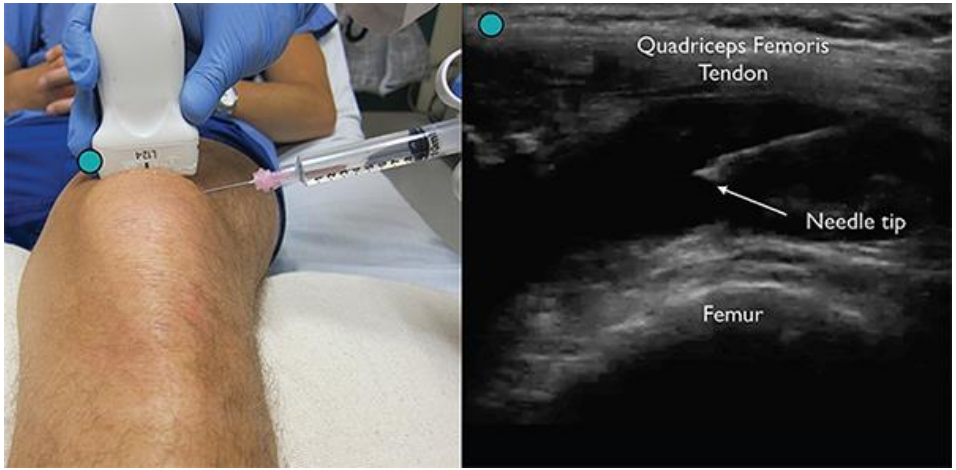

Joint Aspirations

Synovial Fluid Analysis Characteristics

	Volume (mL)	Viscosity	Clarity	Color	WBC/mm^3
Normal	< 3.5	**High**	Clear	Colorless/ Straw	< 150
Noninflammatory	> 3.5	**High**	Clear	Straw/ Yellow	< 3000
Inflammatory	> 3.5	Low	Cloudy	**Yellow**	> 3000
Septic (purulent)	> 3.5	Mixed	**Opaque**	Mixed	> 50,000
Hemorrhagic	> 3.5	Low	Mixed	**Red**	**Similar to blood level**

Synovial Fluid Color and Clarity



Normal | Non-Inflammatory | Inflammatory | Septic | Hemorrhage

Advanced Joints to Be Discussed

- Elbow joint
- 1st CMC Joint
- Foot/ankle joint

Elbow Anatomy

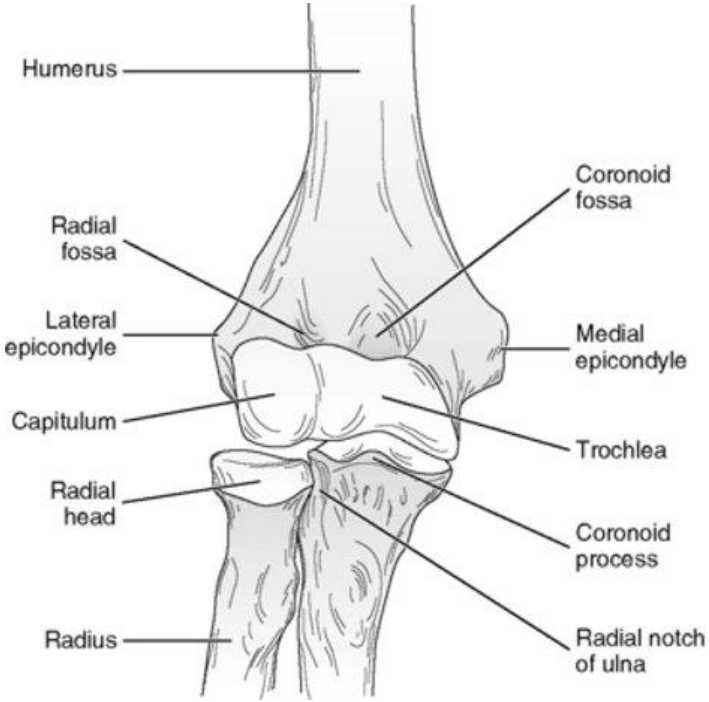

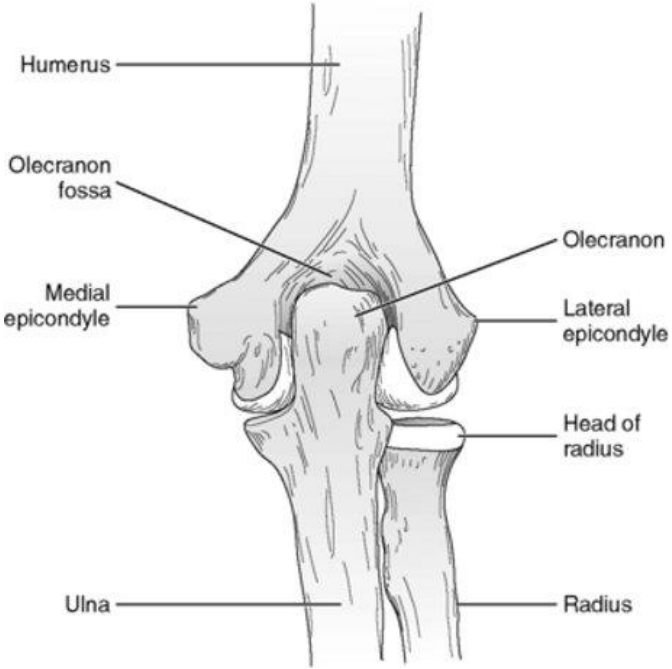

Elbow Injection Indications

- Arthritis
- Lateral Epicondylitis – Tennis elbow
- Medial Epicondylitis – Golfer's elbow
- Ulnar neuritis
- Olecranon bursitis
- Equipment:
  - Syringe: 5-10mL for injection or 10-20mL for aspiration of bursa
  - Needle: 22 gauge 1.5 inches in length or 18 gauge 1.5 inches in length for aspiration
  - Anesthetic: Lidocaine or Ethyl Chloride spray

Elbow Joint Injection

- Positioning:
  - Patient’s resting arm on exam table with access to posterior aspect of the elbow

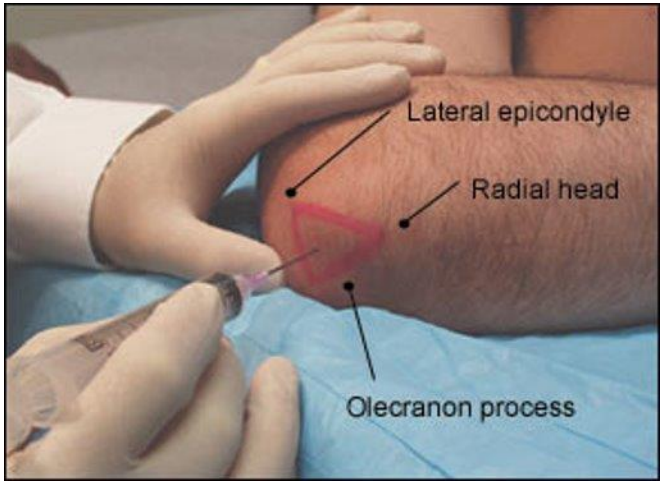

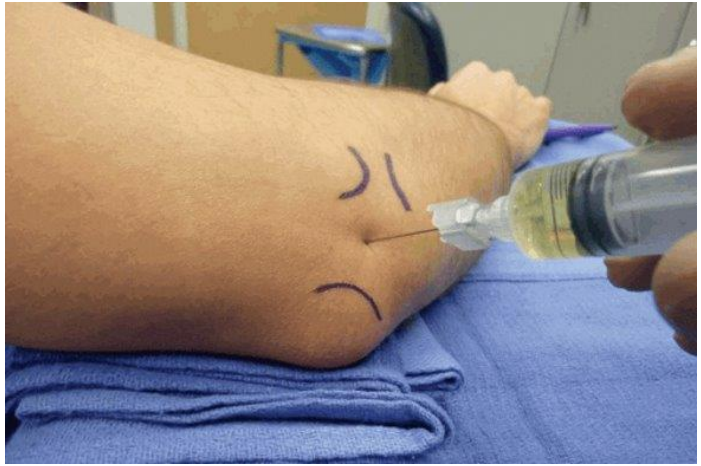

Elbow joint- Ultrasound

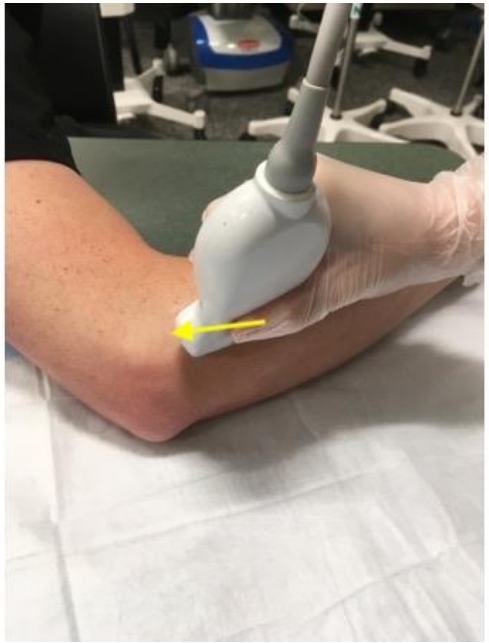

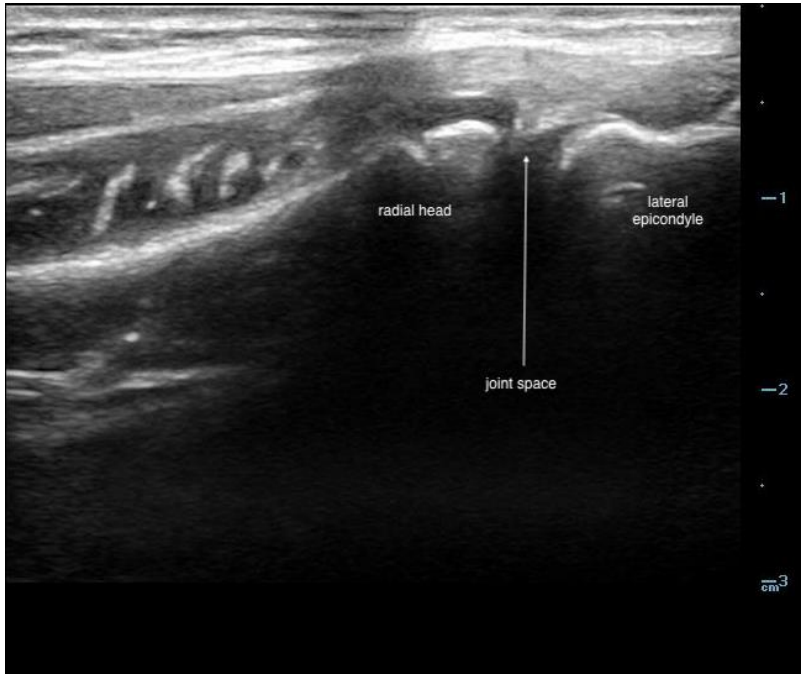

Medial Epicondyle Injection

- Positioning
  - Patient laying supine on exam table with affected elbow/arm externally rotated

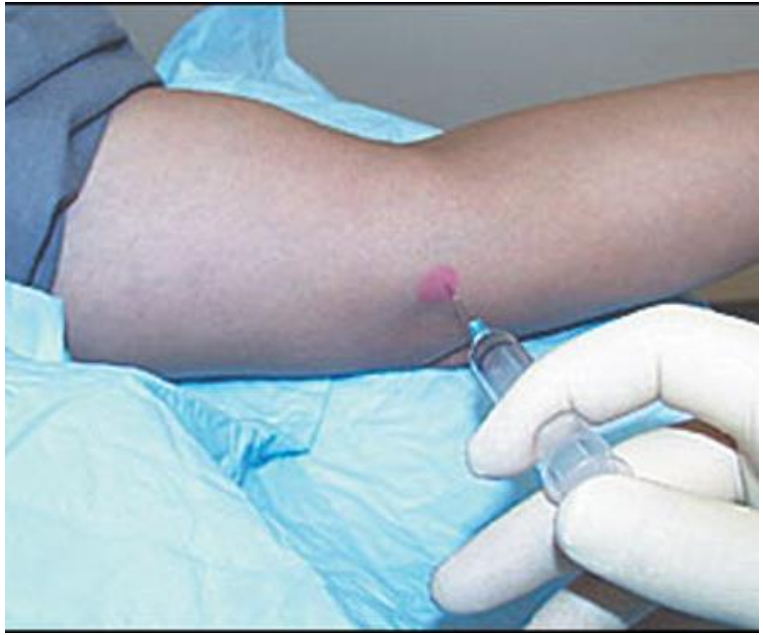

Medial Epicondyle- Ultrasound

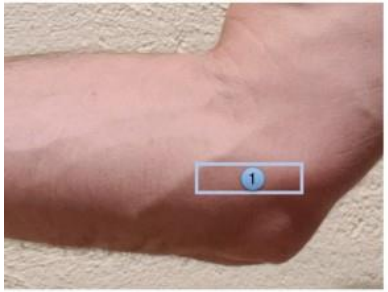

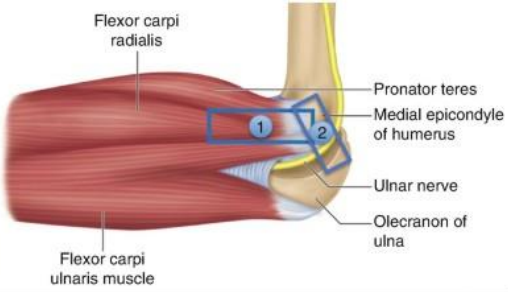

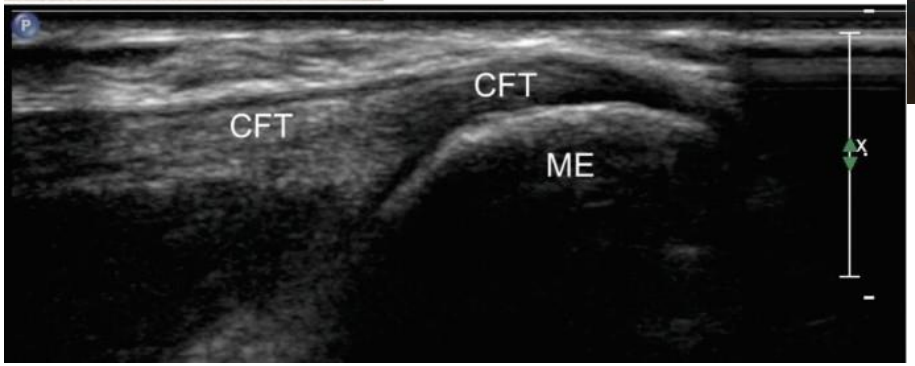

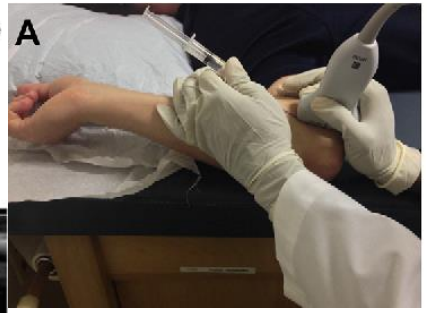

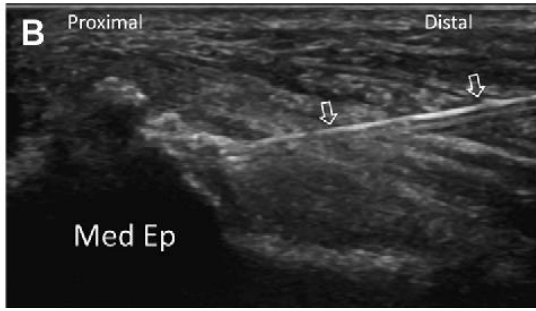

Lateral Epicondyle Injection

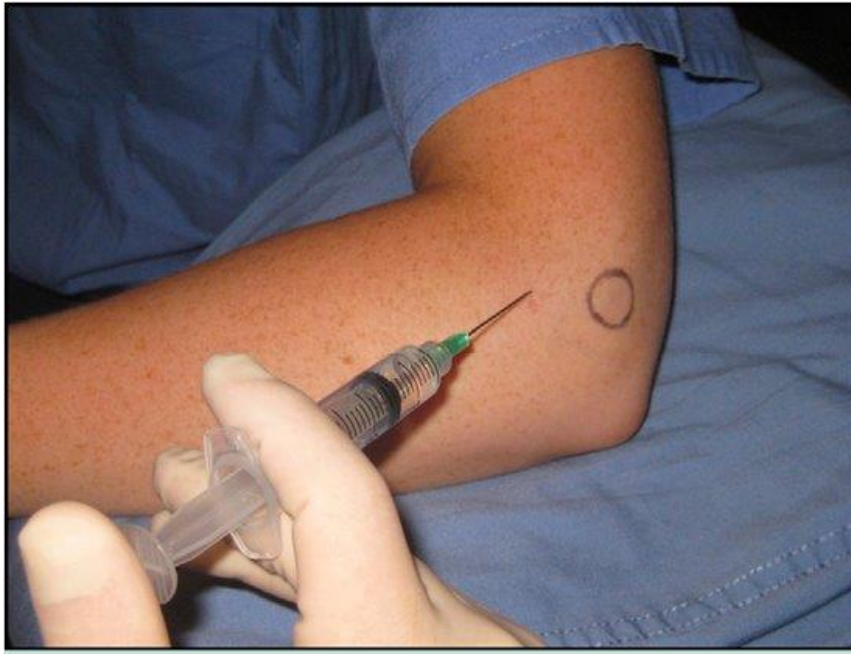

Figure 2 Lateral epicondylitis injection is performed w

- Positioning:
  - Patient sitting in a chair with elbow resting on exam table

Lateral Epicondyle- Ultrasound

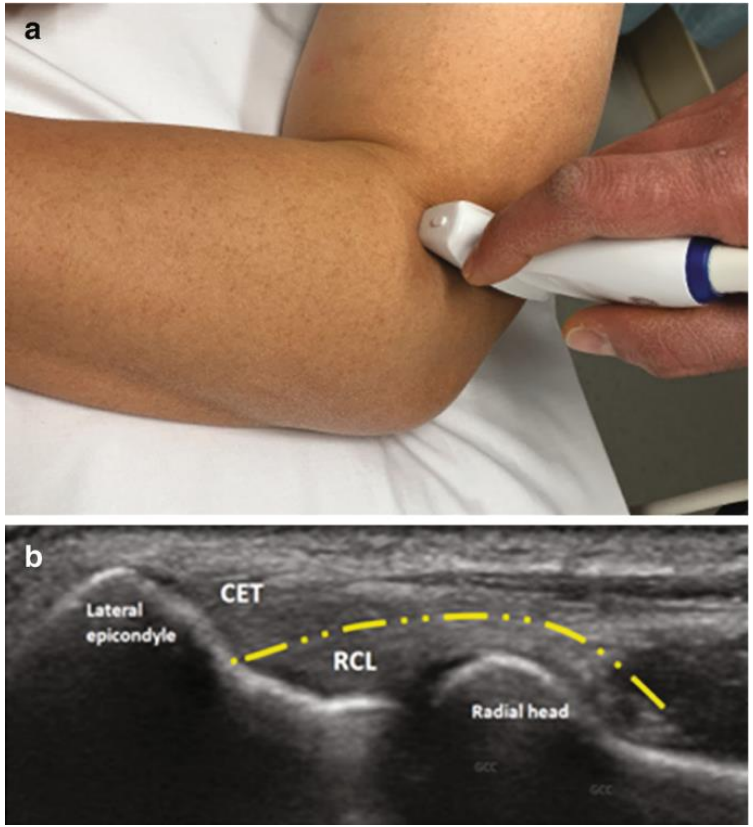

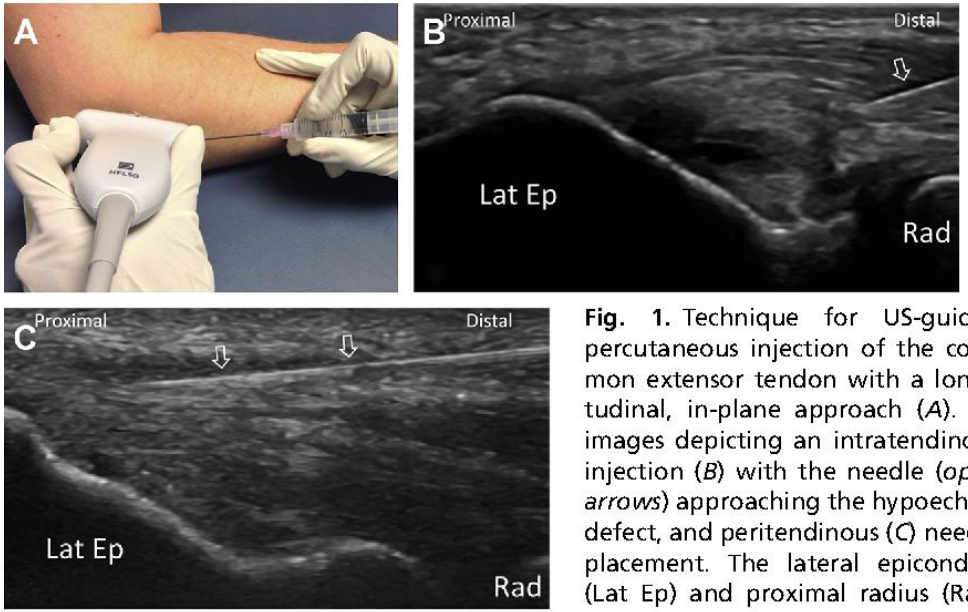

Fig. 1. Technique for US-guided percutaneous injection of the common extensor tendon with a longitudinal, in-plane approach (*A*). US images depicting an intratendinous injection (*B*) with the needle (*open arrows*) approaching the hypoechoic defect, and peritendinous (*C*) needle placement. The lateral epicondyle (Lat Ep) and proximal radius (Rad) serve as bony acoustic landmarks.

Olecranon Bursitis Injection/Aspiration

- Positioning
  - Patient sitting in exam chair with posterior aspect accessible

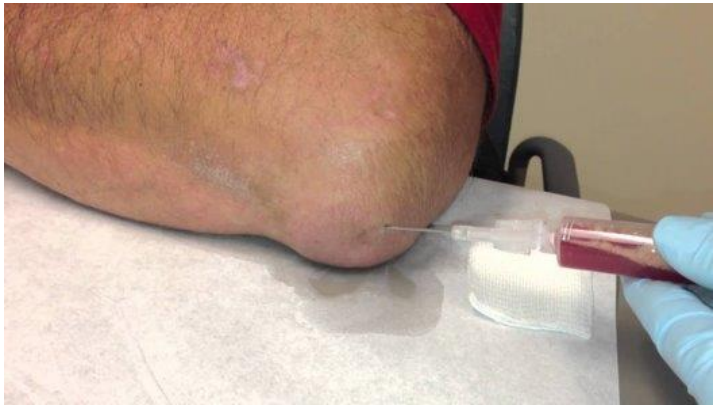

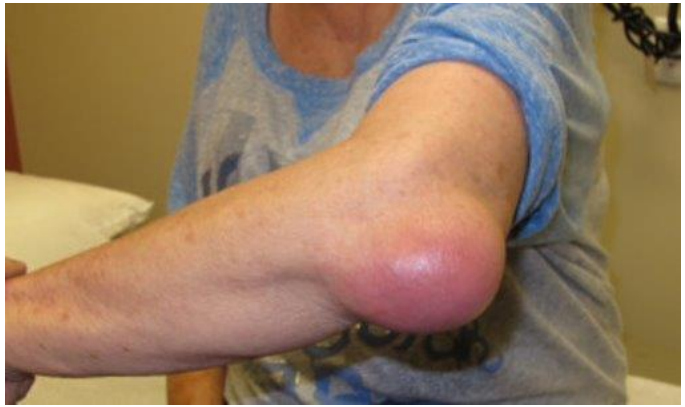

Joint Aspirations

Synovial Fluid Analysis Characteristics

	Volume (mL)	Viscosity	Clarity	Color	WBC/mm^3
Normal	< 3.5	**High**	Clear	Colorless/ Straw	< 150
Noninflammatory	> 3.5	**High**	Clear	Straw/ Yellow	< 3000
Inflammatory	> 3.5	Low	Cloudy	**Yellow**	> 3000
Septic (purulent)	> 3.5	Mixed	**Opaque**	Mixed	> 50,000
Hemorrhagic	> 3.5	Low	Mixed	**Red**	**Similar to blood level**

Synovial Fluid Color and Clarity



Normal | Non-Inflammatory | Inflammatory | Septic | Hemorrhage

1st CMC Joint Anatomy

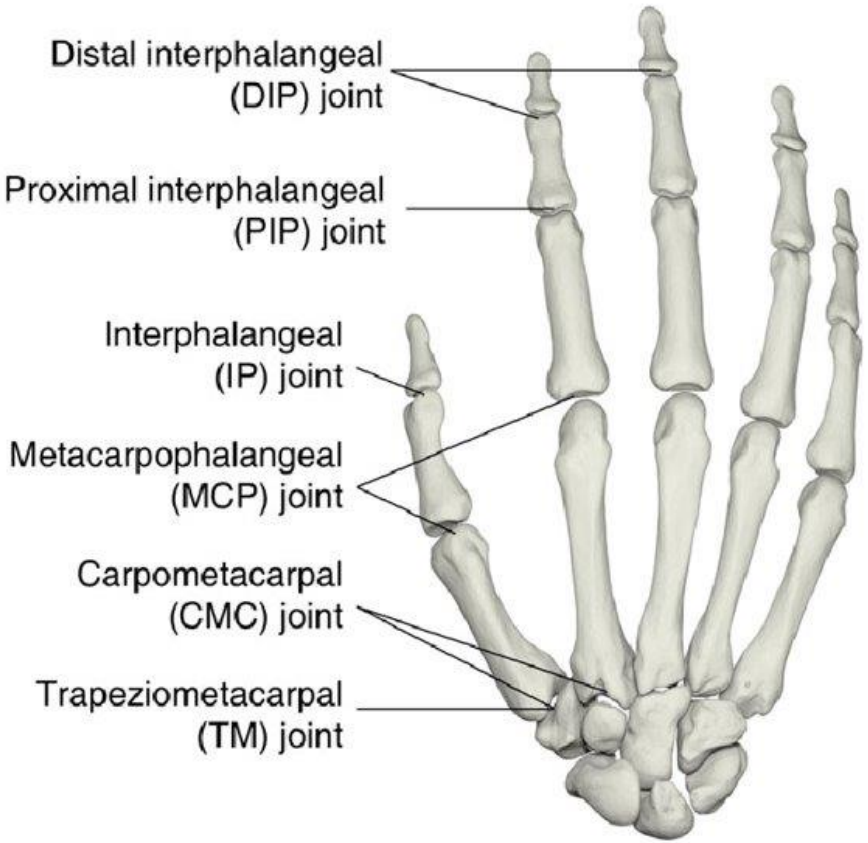

1st CMC Joint Injection Indications

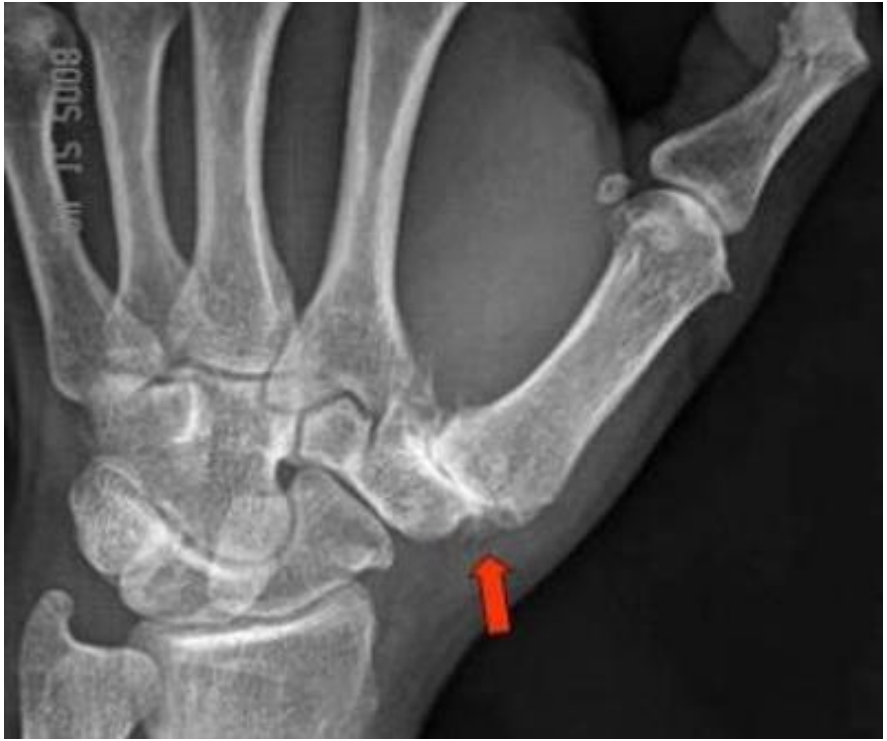

- Arthritis

Positioning: Patient is sitting down with wrist on exam table. Radial side of the wrist is up. May need to distract the thumb to aid in opening the joint space

- Equipment:
  - Syringe: 1mL or 3mL
  - Needle: 25 gauge x 1inch or ½ inch
  - Anesthetic: lidocaine or Ethyl Chloride

Landmarks

- EPL – extensor pollicus longus
- EPB – extensor pollicus brevis
- APL – abductor pollicus longus
- Anatomic snuff box

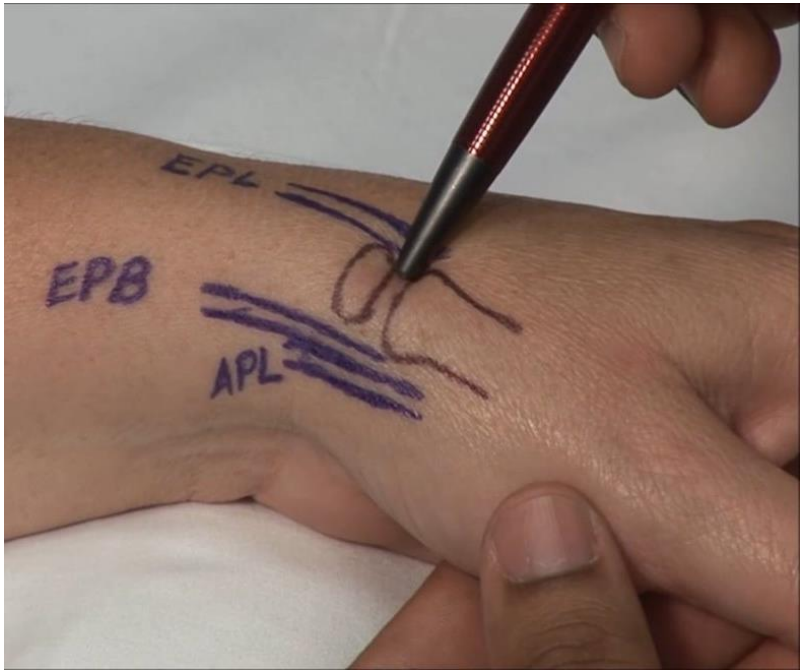

1st CMC Injection With Ultrasound

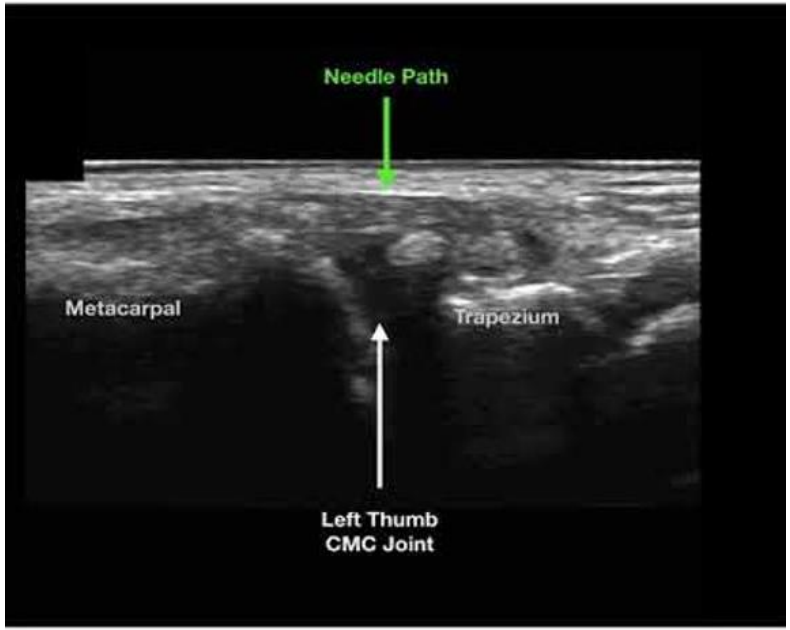

Foot/Ankle Anatomy

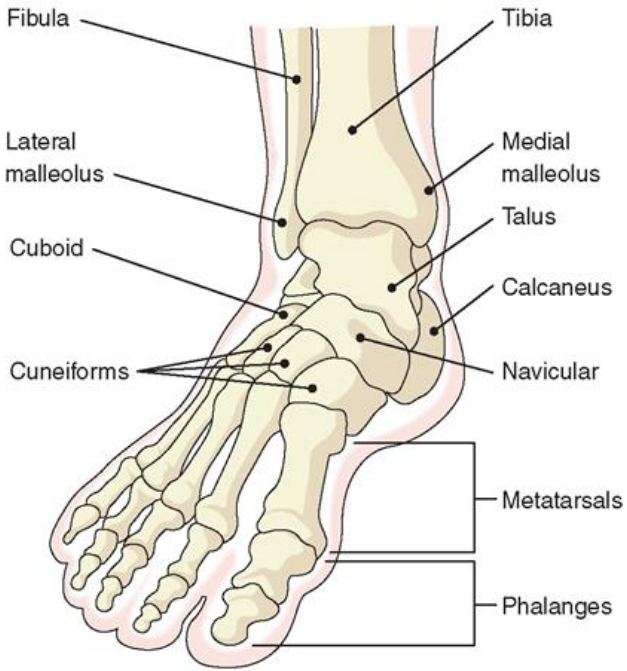

Indications for foot/ankle injections

- Morton's neuroma
- Bunion/1st MTP joint
- Arthritis- cuneiform joints or talofibular joint
- Plantar Fasciitis
- Equipment:
  - Syringe: 3-5mL
  - Needle: 22-25 gauge x 1-1.5 inches in length
  - Anesthetic: Lidocaine or Ethyl Chloride spray

Foot/Ankle

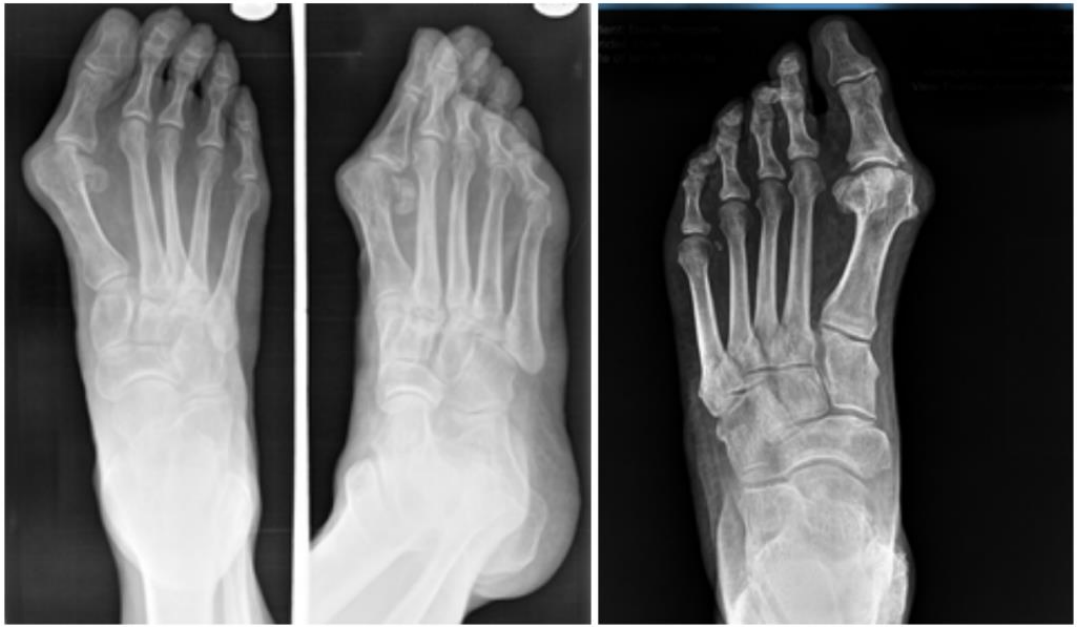

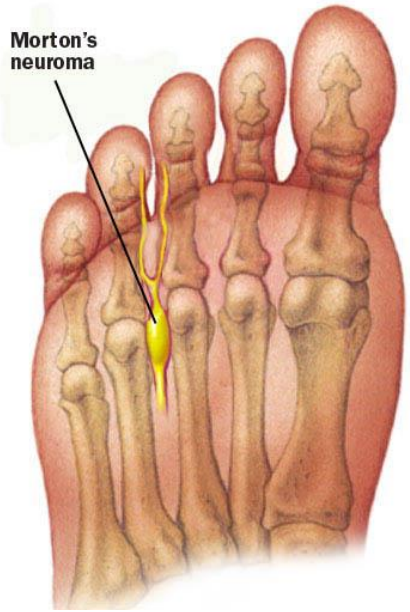

Foot/Ankle

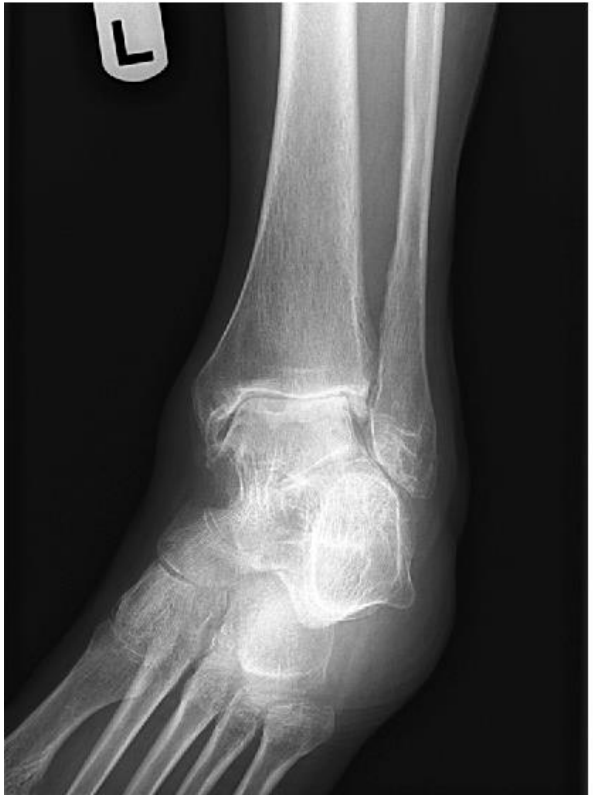

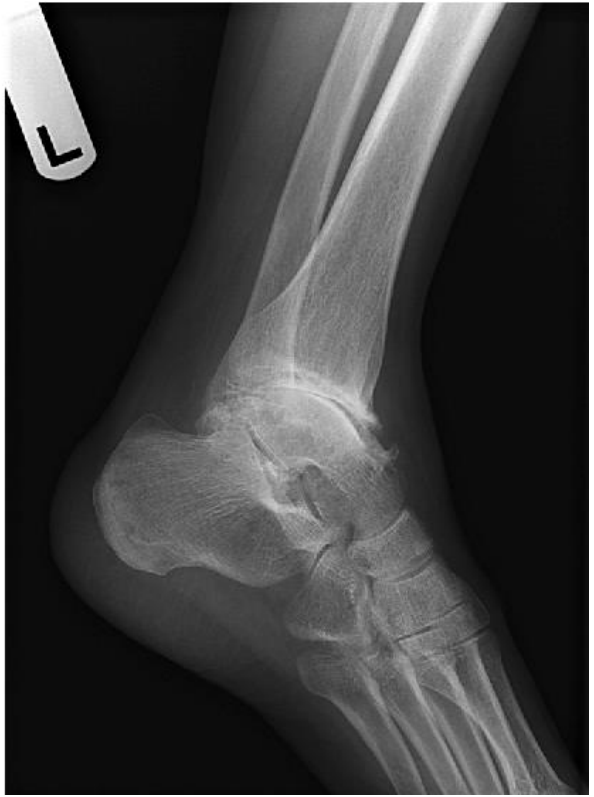

Foot/Ankle

- Positioning:
  - Morton’s neuroma- patient supine on the exam table with knees flexed and foot flat on the exam table

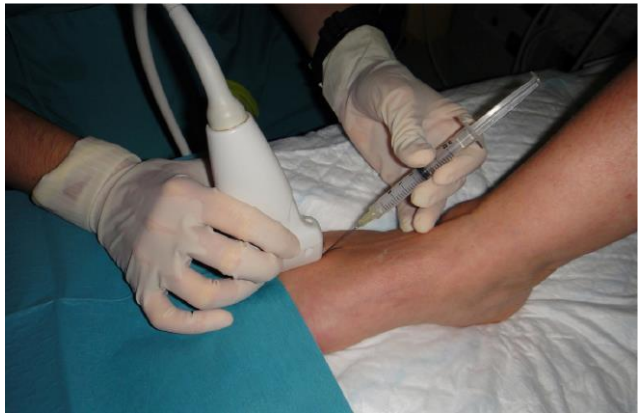

Foot/Ankle – Ultrasound views

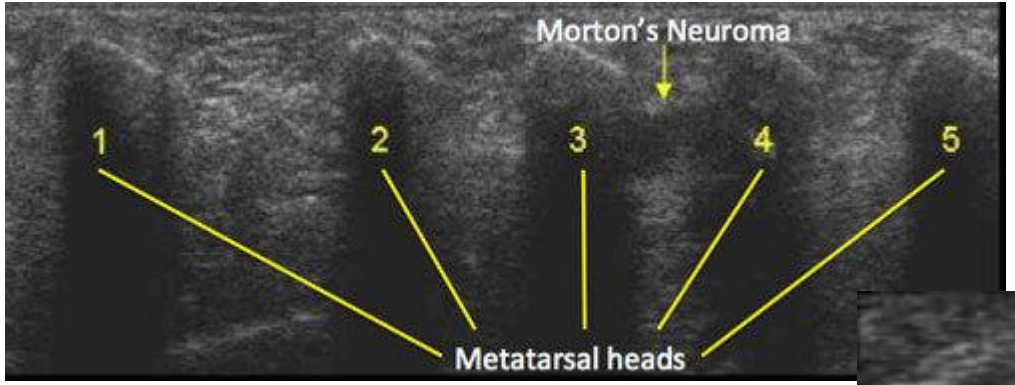

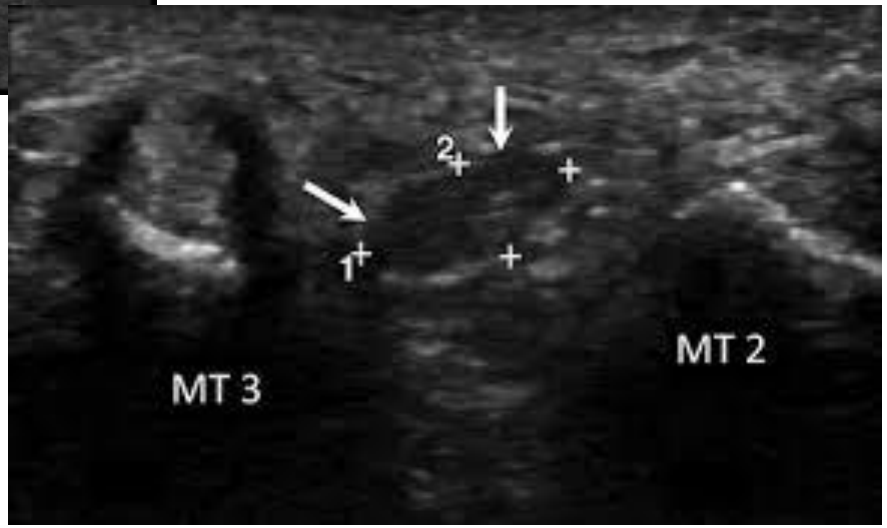

Bunion/1st MTP joint

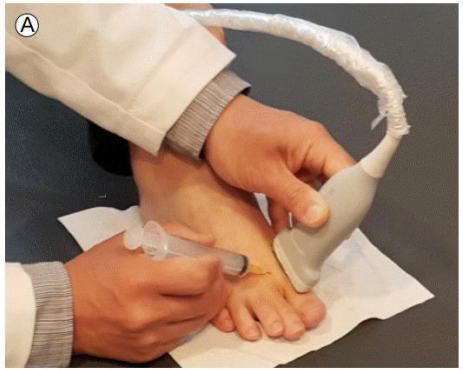

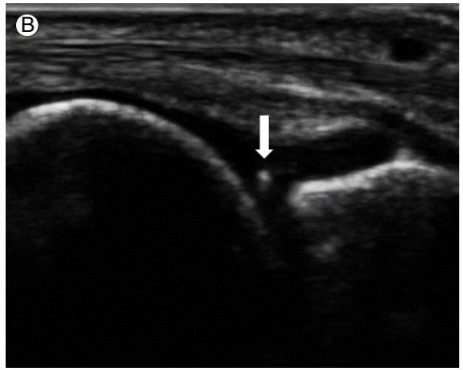

- Positioning:
  - Pt laying supine on exam table with knees handing off the table, flex the knee up and rest heel on the bed of the foot being injected.
- Approach:
  - Identify the joint and distract the joint by pulling in a linear manor on the great toe. Needle will come in from the dorsal aspect of the great toe.

Plantar Fasciitis

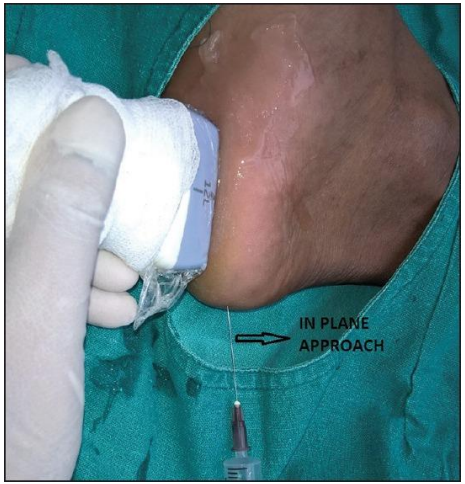

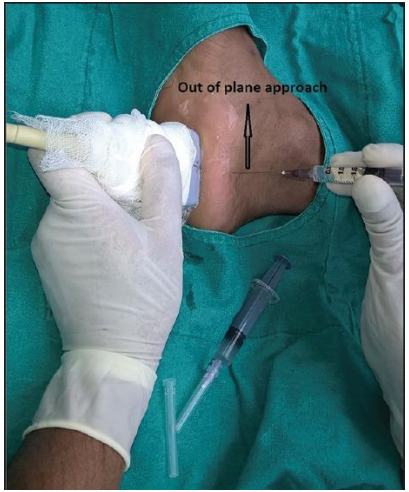

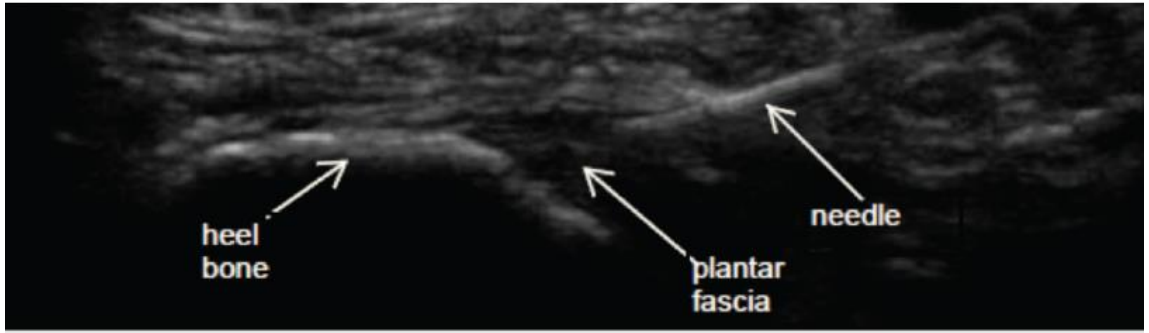

Precision Ultrasound Guided Injection for Plantar Fasciitis

- Positioning:
  - Pt laying in lateral decubitus position- side to be injected down; may want to flex up the opposite side to allow for comfort of pt.
- Approach:
  - Ultrasound plantar surface; needle comes in from the medial (out of plane) or posterior aspect (in plane) of calcanus

Ankle

- Positioning:
  - Pt laying supine with heel off the table or heel on the table
- Approach:
  - Anteromedial- identify the anterior tibialis tendon and go medial to the tendon
  - Ultrasound probe just superior to needle insertion

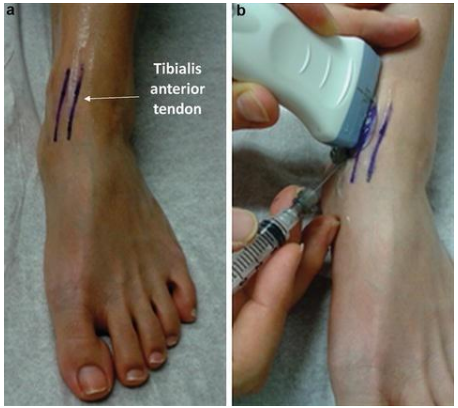

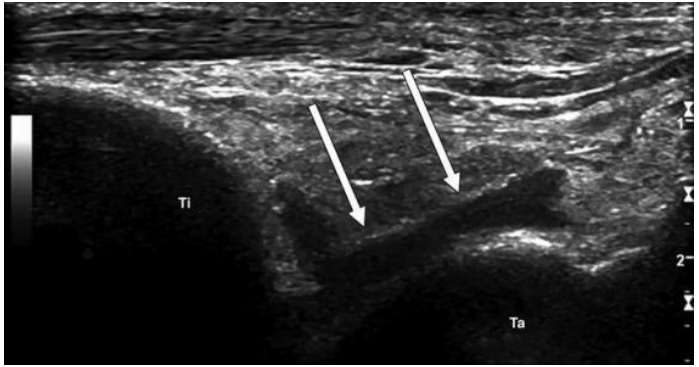

Charcot foot

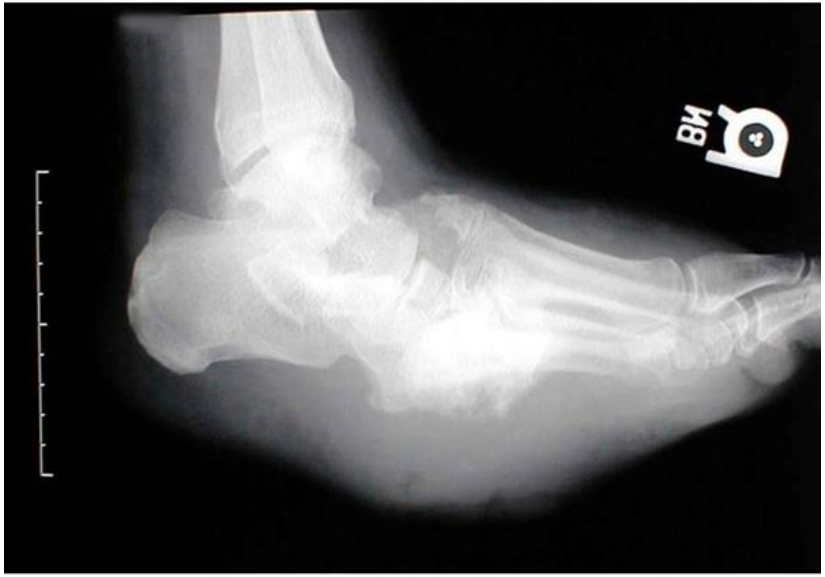

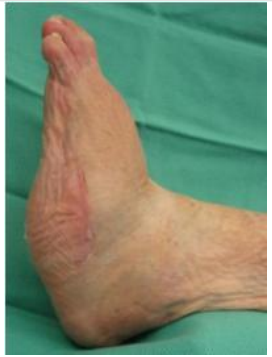

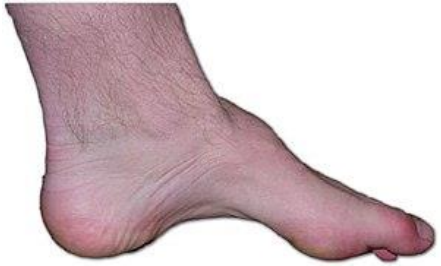

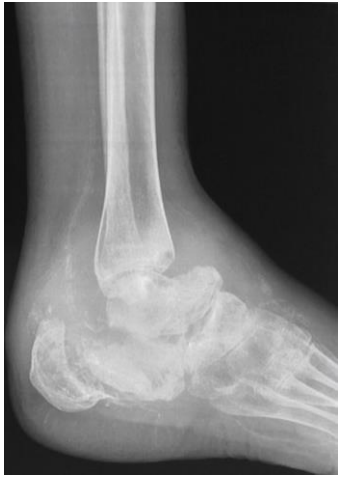

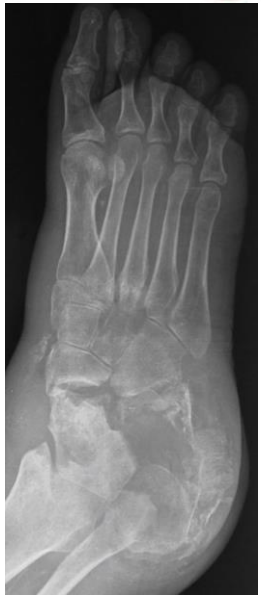

DO NOT INJECT

Resources

- Rheumtutor.com
- https://www.aafp.org/afp/2002/1201/afp20021201p2097-f1.jpg
- https://www.youtube.com/watch?v=jo3gO5BLm4Q
- http://tayloredtraining.ca/movement-recovery/shoulder-pain-and-what-you-need-to-know/attachment/shoulder-2/
- https://www.youtube.com/watch?v=YXtQQAd4n1E
- http://www.imreference.com/rheumatology/rheum-shoulder-pain?tmpl=%2Fsystem%2Fapp%2Ftemplates%2Fprint%2F&showPrintDialog=1
- https://anatomyinfo.com/foot-bones/
- https://www.footandankle-usa.com/types-of-bunions/
- https://www.txfootankle.com/blog/2016/12/1/mortons-neuroma
- https://www.semanticscholar.org/paper/Post-traumatic-ankle-arthritis.-Weatherall-Mroczek/75e0e0e40a9557f4f18c05868e1c8a4a3a0fed46

Resources

- https://anatomyinfo.com/foot-bones/
- https://www.footandankle-usa.com/types-of-bunions/
- https://www.txfootankle.com/blog/2016/12/1/mortons-neuroma
- https://www.semanticscholar.org/paper/Post-traumatic-ankle-arthritis.-Weatherall-Mroczek/75e0e0e40a9557f4f18c05868e1c8a4a3a0fed46
- https://www.orthobullets.com/foot-and-ankle/7047/diabetic-charcot-neuropathy
- https://www.pafootdoctors.com/media/k2/items/cache/68b62085e41e8f225811766f8d5eb2bb_S.jpg
- https://www.ncbi.nlm.nih.gov/pmc/articles/PMC5044731/
- https://arapc.com/foot-pain-psoriatic-arthritis/
- https://www.aafp.org/pubs/afp/issues/2003/1001/p1356.html
- https://www.semanticscholar.org/paper/Ultrasound-guided-steroid-treatment-of-Morton%C2%B4s-Is-Santos-Gomez/16ba53ac71f092b1f3e2afb6ae44971a5ac8c9d7/figure/9

Resources

- https://www.mortonsneuroma.com/blog/ultrasound-examination-effective-identifying-mortons-neuroma/
- https://www.ekjm.org/journal/Figure.php?id=f11-kjm-89-6-654&number=25207&p_name=0106_25207
- https://www.ajronline.org/doi/pdfplus/10.2214/AJR.16.16243?src=recsys
- https://link.springer.com/chapter/10.1007/978-3-319-43133-8_100
- https://link.springer.com/chapter/10.1007/978-3-030-18371-4_20
- https://www.semanticscholar.org/paper/Ultrasound-Guided-Elbow-Procedures.-Sussman-Williams/4fb4c3d5c027b2a7d4dc05939639df6576a03438
- https://www.acep.org/sonoguide/procedures/arthrocentesis/
- https://www.researchgate.net/figure/a-Suprapatellar-longitudinal-scan-of-the-knee-b-Ultrasound-image-of-the_fig1_221887518
- http://reference.medscape.com/features/slideshow/arthro-practice

References

- Bullock, Ian & Borràs, Júlia & Dollar, A.M. (2012). Assessing assumptions in kinematic hand models: A review. Proceedings of the IEEE RAS and EMBS International Conference on Biomedical Robotics and Biomechatronics. 10.1109/BioRob.2012.6290879.
- Cardone DA, Tallia AF. Diagnostic and Therapeutic Injection of the Hip and Knee. *Am Fam Physician*. 2003 May 15;67(10):2147-2152. https://www.aafp.org/afp/2003/0515/p2147.html
- Carmona, R. MSK Injection Techniques, 2020. https://www.rheumtutor.com/
- Fam AG, Lawry GV, Kreder HJ. Musculoskeletal Examination and Joint Injection Techniques. Mosby Elsevier, Philadelphia, PA, 2006.
- https://musculoskeletalkey.com/measurement-of-range-of-motion-of-the-elbow-and-forearm/
- https://i2.wp.com/musculoskeletalkey.com/wp-content/uploads/2020/03/C3-FF1.gif?w=960
- https://ars.els-cdn.com/content/image/1-s2.0-S221425091500013X-gr1.jpg
- https://i.ytimg.com/vi/5eYfuyXczL8/maxresdefault.jpg