RhAPP

RHEUMATOLOGY ADVANCED PRACTICE PROVIDERS

RHAPP NATIONAL CONFERENCE

SEPTEMBER 8-10, 2022

Adult Idiopathic Inflammatory Myopathy

Jeannette Hart PA-C MCHS
Kadlec Clinic-Rheumatology
Tri-Cities, WA

Disclosure Policy

All individuals in control of the content of continuing education activities provided by the Annenberg Center for Health Sciences at Eisenhower (ACHS) are required to disclose to the audience all relevant financial relationships related to the content of the presentation or enduring material. Full disclosure of all relevant financial relationships will be made in writing to the audience prior to the activity. All other staff at the Annenberg Center for Health Sciences at Eisenhower and RhAPP have no relationships to disclose.

Faculty Disclosures

Speakers Bureau:

- AbbVie
- AstraZeneca
- Sanofi

Objectives

- Weakness vs. Fatigue vs. Malaise
- IIM then and now
- IIM- Clinic serological Subtypes
- Clinical Vignettes
- Abstract Review

Adult IIM- It’s Complicated

- Heterogeneous group of disorders
- Muscle weakness +/- extramuscular
  - Lungs, skin, heart, joints
- Does NOT include
  - neurologic, metabolic, toxin/drug induced, or infectious inflammatory myopathies
- The presence of myositis on biopsy alone doesn’t diagnose IIM
  - Inflammation can be secondary to muscle damage
  - Inflammation can be seen in hereditary muscle diseases (LGMD)

Weakness… Fatigue…Malaise

<u>Fatigue</u> differs from weakness -fatigue is a loss of strength with activity that recovers with rest.

<u>Malaise</u> differs from weakness- malaise is a subjective feeling of weakness without objective findings.

Investigate the history of "weakness"

Weakness is…

- A reduction of muscle power:
  - difficulty climbing stairs
  - getting up from toilet
  - stepping up a curb
  - standing from a squat
  - washing/brushing hair
- MMT: 1-5

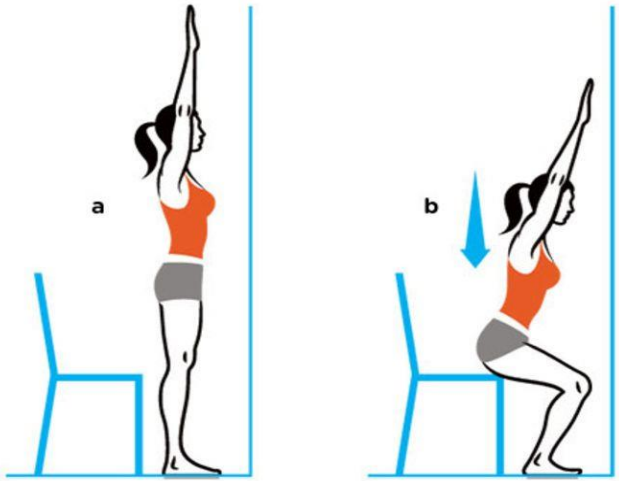

Diagnosing Adult IIM Prior to 2017
PM, DM

<u>Bohan and Peter Criteria of 1975</u>

1) Symmetrical proximal muscle weakness
2) Muscle biopsy evidence of myositis
3) Elevation in serum skeletal muscle enzymes
4) Characteristic electromyography pattern of myositis
5) Typical rash of dermatomyositis

- Definite: #5 + any three 1-4
- Probably: #5 + any two 1-4
- Possible: #5 + any one 1-4

Discovery of MSAs since Peter and Bohan

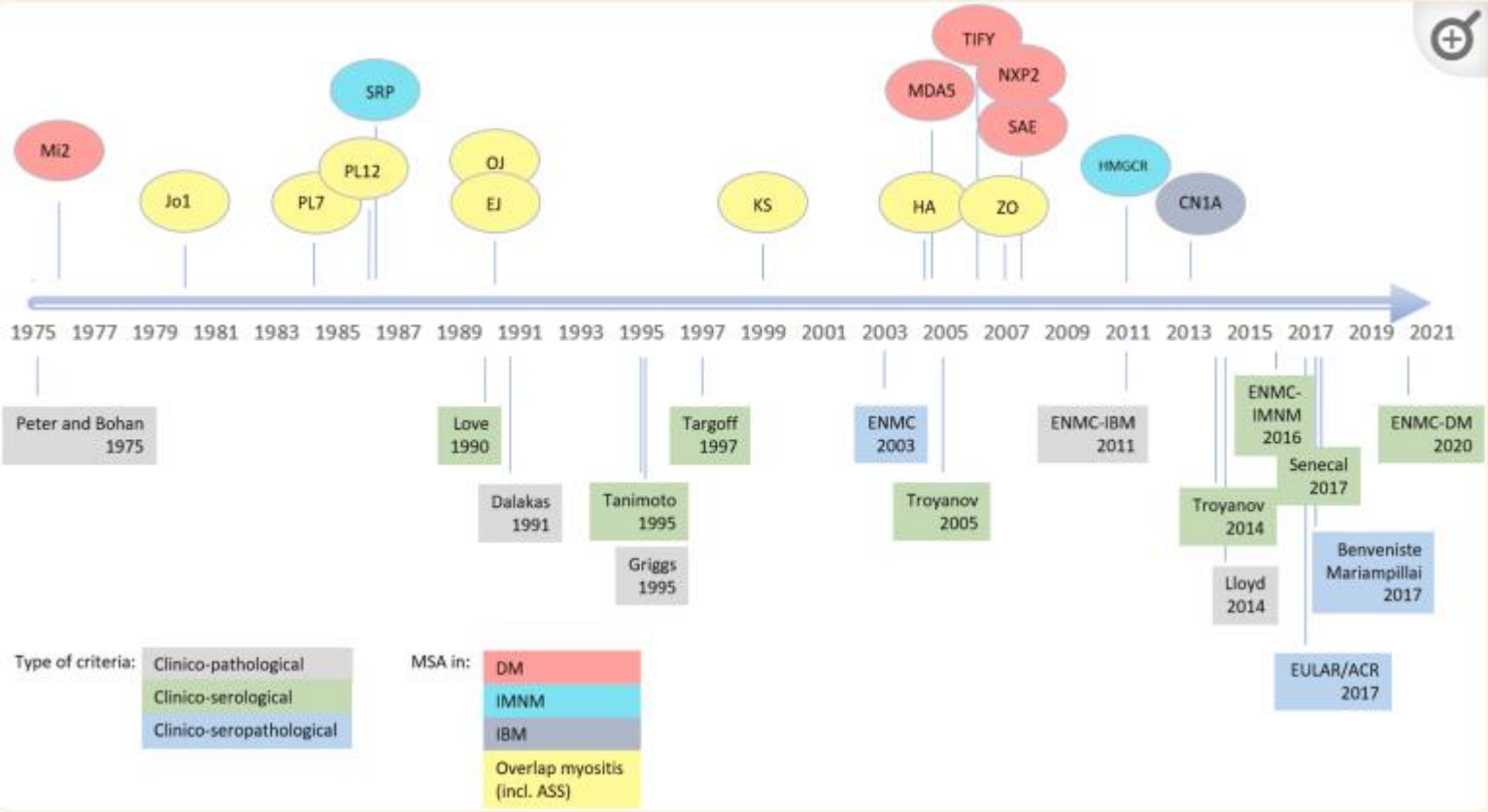

2017 EULAR-ACR Criteria

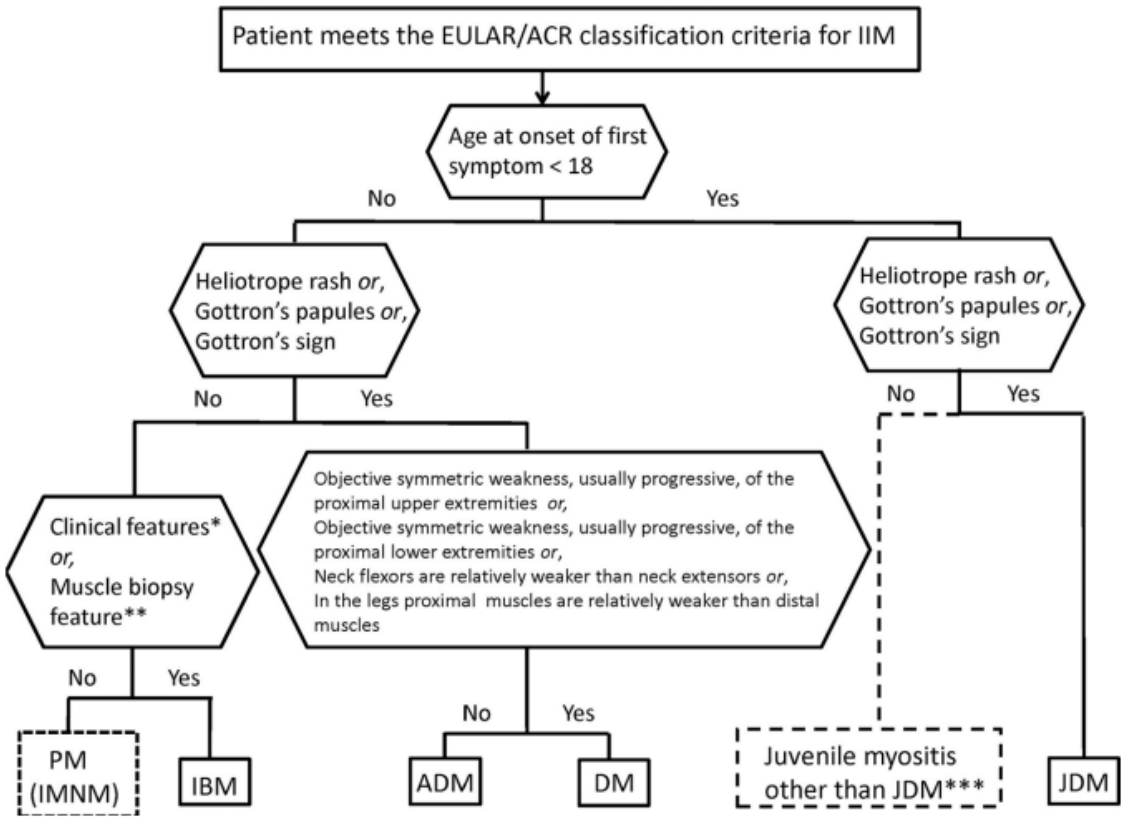

Adapted from Lundbeg et.al (2017). *European League against Rheumatism/American College of Rheumatology classification criteria for adult and juvenile idiopathic inflammatory myopathies and their major subgroups*. Annals of the rheumatic diseases

ClinicoSEROLOGICAL subtypes

- DM: Dermatomyositis / Amyopathic (amyotrophic)
- IMNM: Immune-mediated necrotizing myositis
- IBM: Inclusion body myositis
- PM: Polymyositis
- OM: Overlap myositis
- ASS: Anti-synthetase syndrome

Overview of auto-antibodies and their associated clinical features

	Auto-antibody	Frequency	Typical clinical features
ASS	Anti-tRNA: Jo-1, PL-7, PL-12, HA (YRS/Tyr), OJ, KS, ZO, EJ	anti-tRNA: 30% in myositis Jo-1: 15-20% in myositis PL-7 and PL-12: each 3-4% All others <2%.	Higher rate of ILD and mortality in PL-7/PL-12 than Jo-1
OM	Anti-SS-A/Ro52/Ro60 SS-B/La	SS-A: up to 19% in myositis, 25% in OM, SS-B: 7% in myositis, 12% in OM Ro52 often together with anti-synthetase, e.g. 56-72% of Jo-1.	Association with Sjögren's syndr., SLE and systemic sclerosis. Ro52 more common in myositis than Ro60; both occur in CTD. Ro52 and Jo-1-double positive: high rate of malignancies, poorer prognosis.
	U-snRNP	up to 10% of myositis	Associated with CTD, SLE and systemic sclerosis. Often good prognosis.
	PM/Scl	~8-10% of myositis	Associated with systemic sclerosis. Often severe disease course and insufficient treatment response.
	Ku	up to 20-30% in OM	Associated with systemic sclerosis, SLE and CTD. High rate of ILD, which does not respond well to glucocorticosteroids.
DM	Mi-2	5-10% in DM	Classical DM
	MDA5	15-30% in DM	Often amyopathic DM, often ILD.
	TIF-1α/β/γ	~20% in DM	Malignancy common (75%). Most common in JDM–without tumor.
	NXP-2	10-15% in DM	Malignancy frequent (37.5%). Second most common antibody in JDM–without malignancy, but often calcinosis.
	SAE	2-8% in DM	Often amyopathic and with ILD.
NM	SRP	5% in myositis	Often severe with muscle atrophy, ILD and dysphagia. Often basic immunosuppressive treatment regimen not sufficient.
	HMGCR	5-8% in myositis	High frequency of malignancy.
IBM	cN1A	~30% in IBM	Sjögren or SLE positive by 20-30%, even without muscle symptoms. In IBM: more severe disease course, dysphagia and higher mortality.

Adapted from: Schmidt, J. (2018). Current classification and management of inflammatory myopathies. *Journal of Neuromuscular Diseases*, *5*(2), 109–129. https://doi.org/10.3233/jnd-180308

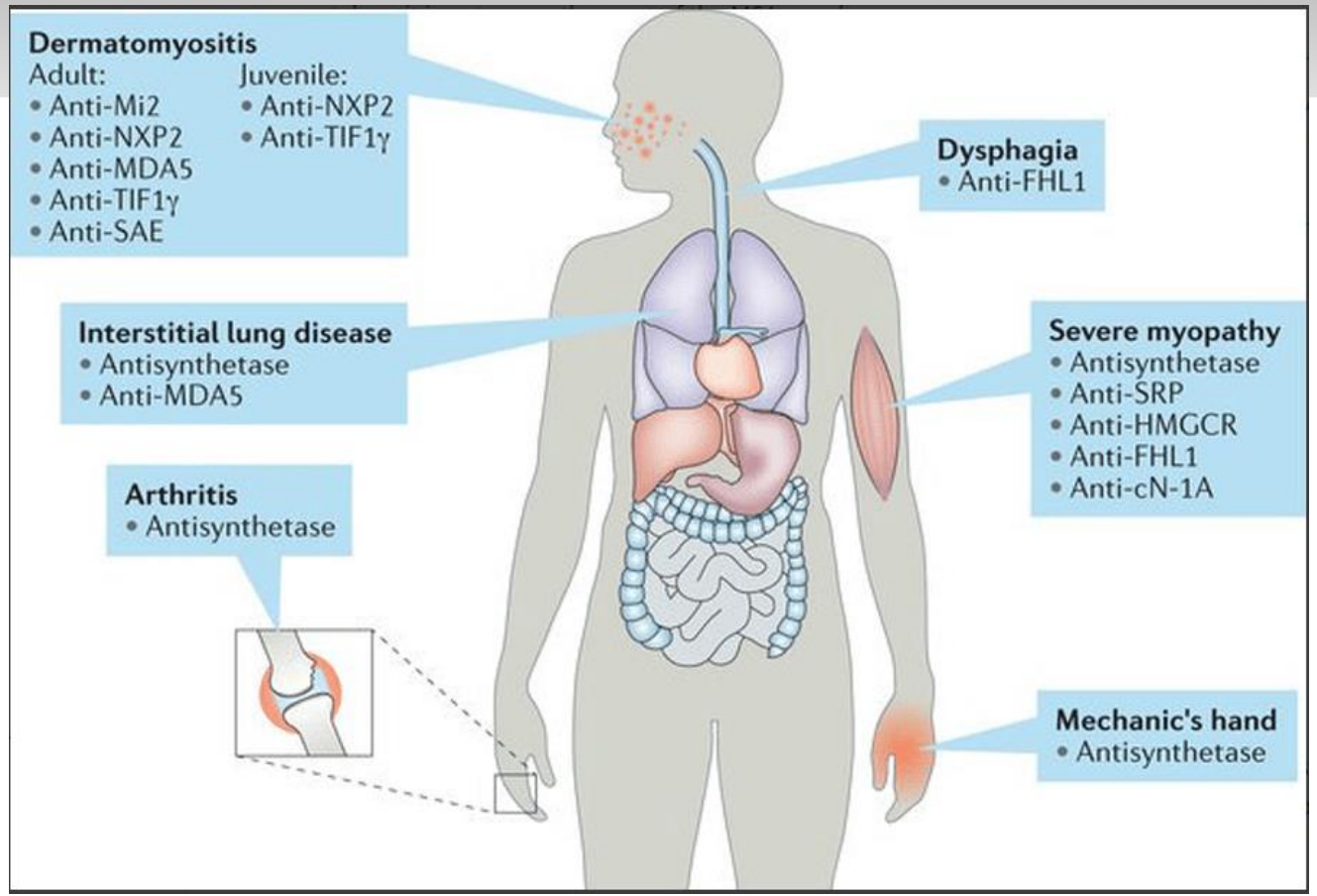

Adapted from understandingmyositis.org

Dermatomyositis and Amyopathic DM

- **Rash** is typically the first clinical manifestation
- **Muscle disease** follows or coexistent with the rash. Proximal muscle weakness
  - 70% having elevated muscle enzymes
  - 20% to 30% having normal CPK (amyotrophic DM)
- **MSAs** found in 50% to 70% and identify clinical subsets.
  - Anti-Mi2
  - Anti-SAE
  - Anti-TIF 1 gamma
  - Anti-NXP2
  - Anti MDA5
- **Muscle pathology:** perimysial/perivascular inflammation with (50%) or without (50%) perifasicular atrophy.
- **EMG**: motor unit action potential with small amplitudes,short durations, and early recruitment

DM ADM Skin manifestations

- Heliotrope rash/ eye lid edema
- Gottron's papules
- V-sign rash
- Shawl-sign rash
- Holster-sign rash
- Nailfold abnormalities
- Psoriasiform lesions (scalp)

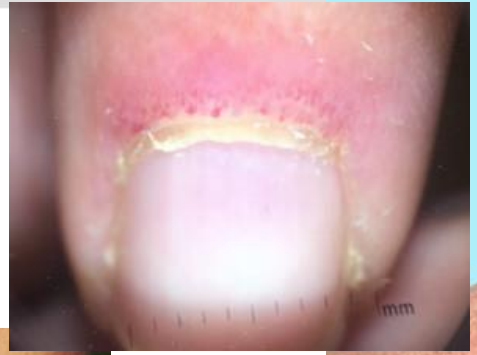

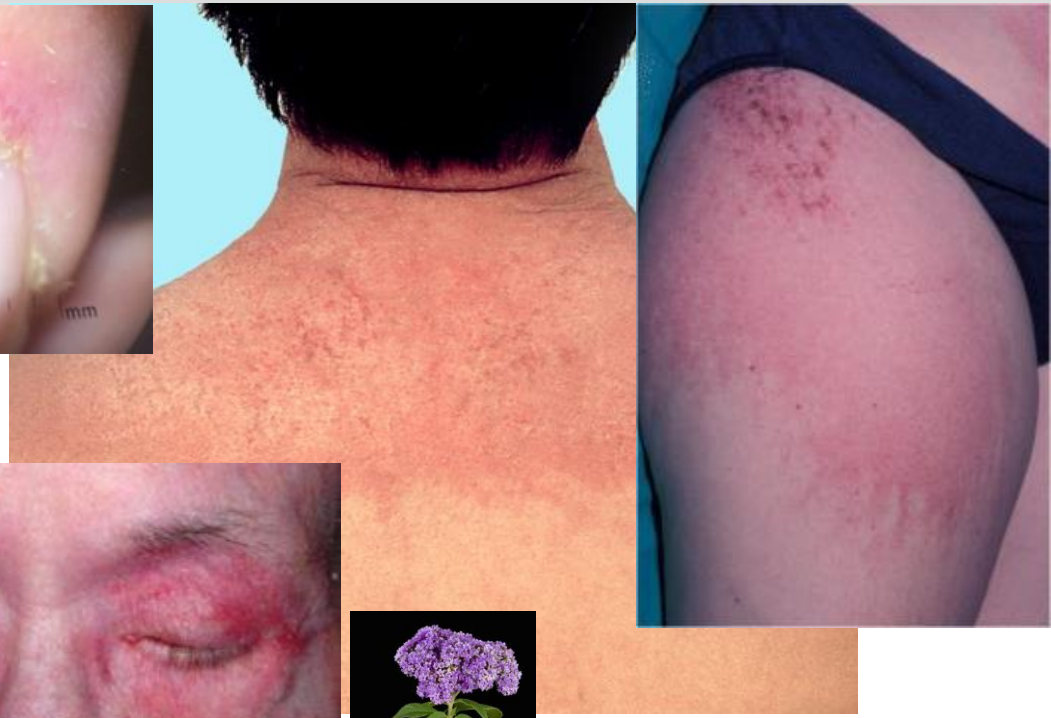

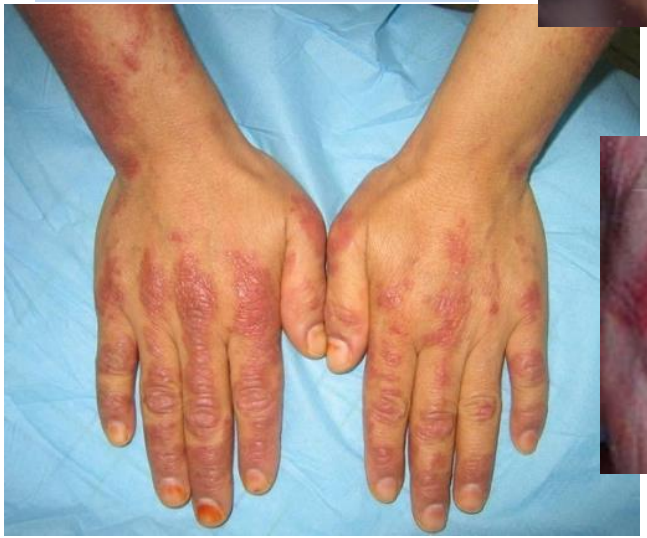

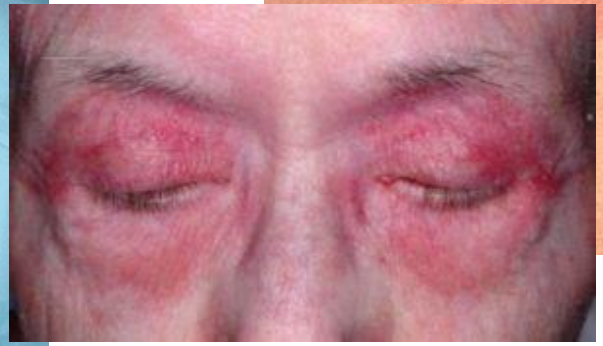

Clinical subsets of DM defined by MSA antibodies

Table 1: Myositis-specific antibodies associated with DM

	Prevalence (%)	DM	Other clinical features	Anti-synthetase syndrome	Cancer	Prognosis	Treatment response
Anti-Mi 2	10	DM rash	Mild myositis	No ILD	No cancer risk	Good prognosis	Excellent treatment response
Anti-SAE	1	DM rash--severe Periungual lesions	Dysphagia	Mild ILD	No cancer risk	Good prognosis	Excellent response to treatment
Anti-TIF 1 gamma	10--15	Aggressive skin lesions		Low prevalence of ILD	High association with cancer in adults	Poor prognosis	Poor response due to underlying malignancy
Anti - NXP2	1--5	Adult and juvenile DM Calcinosis cutis	Muscle contracture, atrophy	Joint contractures Arthritis ILD	High association with cancer	Poor prognosis	Poor response to treatment due to underlying malignancy
Anti - MDA5/CADM 140	15-20	Severe necrotizing skin rash with vasculopathy Tender papules over palms	Amyopathic	Anti- synthetase syndrome with rapidly progressive ILD	Risk of cancer	Poor prognosis	High morbidity and mortality due to rapidly progressive ILD

Adapted from: Khadilkar, S. V., & Dhamne, M. C. (2020). What is new in idiopathic inflammatory myopathies: Mechanisms and therapies. Annals of Indian Academy of Neurology. https://doi.org/10.4103/aian.aian_400_19

Anti-Synthetase Syndrome

Myositis	ILD	Arthritis	Raynaud's	Fever	Mechanics Hands

- ✓ Presentation variable- based on MSA/MAA
- ✓ Various autoantibodies to aminoacyl transfer RNA (tRNA) synthetase
  - ✓ (Jo1) (PL-7),(PL-12), (EJ), (OJ)
- ✓ Helps differentiate from DM
- ✓ High risk ILD but lower risk of cancer
- ✓ Might present only with ILD

Immune Regulated Necrotizing Myopathy (IMNM)

Anti-SRP	Anti- HMGCR
Neck weakness, dysphagia, resp insufficiency	Sensitive and specific
Incomplete response to steroids	Prior statin exposed patients (risk factor)
Seasonal pattern - Autumn	Progressive weakness and dysphagia
Biopsy- endomysial fibrosis, little inflammation.	Needs aggressive treatment

Inclusion Body Myositis (IBM)

Biopsy- distinctive intranuclear and cytoplasmic filamentous inclusion and vacuoles.

Inclusion-Body Myositis (IBM)

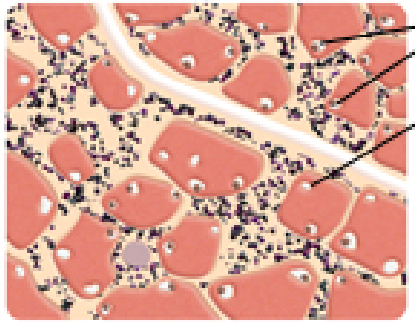

IBM is characterized by muscle fibers that contain empty, bubble-like spaces (vacuoles) and clumps of cellular material (inclusion bodies). Inflammatory cells can be seen between the fibers.

IBM

- Commonest cause of IIM in patient > 50 yo.
- Asymmetric muscle weakness
  - Quadriceps, forearm flexors and ankle dorsiflexors
  - Difficulty swallowing in up to 60%
- Unresponsive and slowly progressive
- No extra-muscular features
- MSA: cN1A

Overlap Myositis

Co-occurrence of inflammatory myopathy *AND* CTD

- Myositis associated anitbodies (MAA)
- SSA/SSB are the commonest (>30%)
- OM has a higher risk for ILD, arthritis and cancer
- 5-17% of scleroderma patients have myositis

PM is RARE

- Accounts for only 8% of IIM
- Diagnosis of exclusion

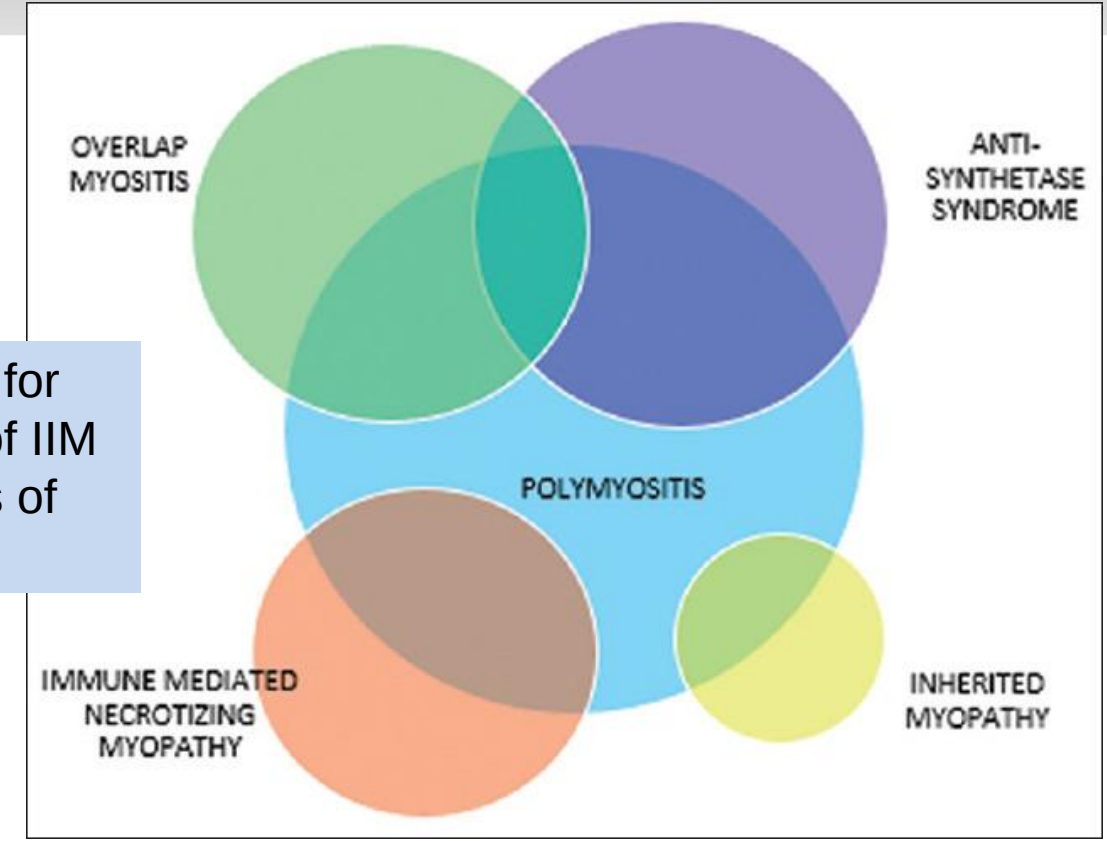

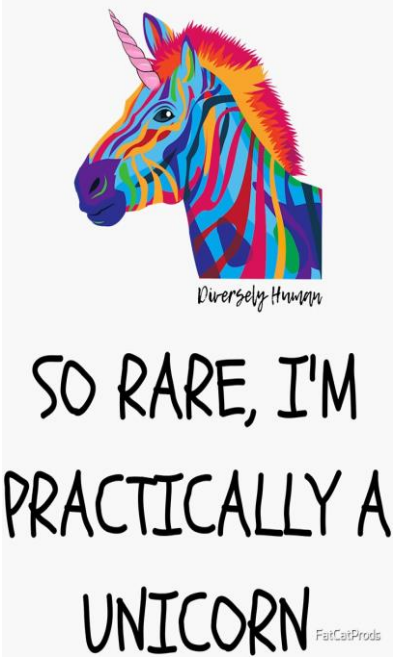

Khadilkar, S. V., & Dhamne, M. C. (2020). What is new in idiopathic inflammatory myopathies: Mechanisms and therapies. *Annals of Indian Academy of Neurology*. https://doi.org/10.4103/aian.aian_400_19

Treatment is difficult

- IIM is heterogenous and lacks disease activity markers.
- Use Immunosuppressants + Corticosteroids
- IVIG/Rituximab - some response seen especially in DM
- Plasma exchange has NOT been proven effective.
- Calcineurin inhibitors, tacrolimus and cyclosporine
  - Inhibit T-cell mediated immunity

Clinical Vignette- 52 yo F (2012)

- Increasing proximal weakness in shoulders and thighs- difficulty getting up from a low chair
- Rash on hands- peeling and red
- Denies SOB
- PCP provided prednisone 40mg daily- improved weakness- referral made to rheumatology

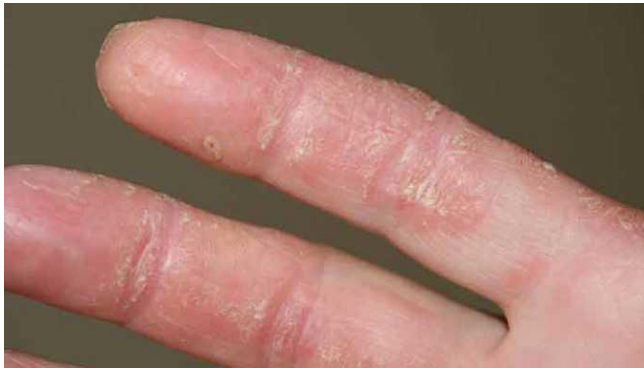

52 yo F (2012)

(+) Objective findings

- Elevated LFT, +ANA, elevated aldolase, elevated CK
- Bilateral lung crackles
- Decreased power in proximal muscles
- Erythematous scaly rash on the palms of the hands with fissuring skin

Rheum Dx ASS:

- Ordered EKG,PFT, CT C/A/P, asked PCP to do age appropriate CA screening
- Labs: Aldose (no MSA available), safety testing for DMARD
- Given Prednisone 60mg daily- consider mtx

52 yo F (2012)

1st visit back: Dramatic response to prednisone: In strength and skin

Labs :
Repeat ANA IFA (-)
ESR nl
Aldolase 45,
AST 140 ALT 111
CPK 6272
Jo-1 positive (6.4)

CT Chest - ILD
CT abd/pelvis -nl
PFT-mod restrictive
DEXA- normal
Echo- neg for PAH
Opted not to biopsy

Pred 60mg daily
Mtx 20mg weekly
Refer to pulm

52 yo F (2012)

- Added Imuran- BUT not tolerated
- Refractory- heliotrope rash and LLE increased weakness
  - D/C mtx start MMF titrate up to 3 grams daily
- MMF at 3 g daily unable to taper prednisone <20mg daily.
  - weakness and chronic cough
- Start Rituxan 2015
- Response! Tapered Prednisone and MMF
- Rituxan (RA protocol) q 6 months -no relapse

Clinical Vignette- 29 yo M (2015)

- ED tech-presenting with S/T MCP, elbows and feet.
- Rash on extensor surfaces of mcp and pips. Rough skin on elbows and soles of feet
- Previously diagnosed with PSA
- Rash remained through mtx, TNFi, IL-17
- Joints improved- skin never improved

29 yo M (2015)

- Why wont the skin respond?
- Frequent flares and fatigue
- Drew Jo-1 and CK and sent to dermatology
- Dermatology treated as psoriasis
- CK normal JO-1 +
- Denied weakness and SOB

29 yo M (2015)

- Somewhat stable on Mtx and IL-17
- Screening PFT resulting in a decreased DCLO
- CT + for ILD despite normal CXR and lung sounds
- = Amyopathic DM
- D/C IL-17 maintain on mtx referred to pulm.
- FU next month

65 yo F (2018)

- Referred due to: joint pain/swelling +RF/-CCP, + ANA (+SCL- 70, + anticentromere)
  - MCP synovitis and ulnar deviation
- She was seen by pulmonology possible ILD
  - PFT: supported asthma only
- Echo in 2013 was satisfactory
- Previously treated for sero- RA for years
  - joints improved

65yo F

- New to me: rash on face and hands despite TNFi
- Tried and failed multiple DMARDs- intolerance. *Felt best on IL-6 but reacted
- Complicated by anxiety
- Sent to dermatology - persistent rash
  - psoriasiform acanthosis, slight spongiosis and cytotoxic effect. Psoriasiform-cytotoxic presentation of dermatomyositis.

65 yo F

- Started IIM work up
- Patient develop Breast Cancer
- + PM-SCL-100
- Dx Changed to Overlap Myositis
- Maintained on Rituxamab
- Prognosis guarded.

Abstract- OP0161 (EULAR)

TREATMENT PATTERNS OF IDIOPATHIC INFLAMMATORY MYOPATHIES: RESULTS FROM AN INTERNATIONAL COHORT OF OVER 1,400 PATIENTS

-Aoude M, Gupta L, Hmamouchi I, *et al*

OP0161

- Objective- Evaluate frequency and patterns of treatments used for IIM based on type, world region and organ involvement
- Took data from CoVAD self reporting survey
- 1418 patients – most common subset DM

The most used treatments for IIM

1) Immunosuppressants 49%
   - Methotrexate, MMF, Azathioprine, Cyclosporine Tacrolimus Leflunomide Sulfasalazine Cyclophosphamide
2) Corticosteroids 40.8%
3) Antimalarials 13.8%
4) IVIG 9.4%
5) Biologics 4.3%

Abstract ACR 2021

Predictors of Rapidly Progressive Interstitial Lung Disease and Mortality in Patients with Autoantibodies Against Melanoma Differentiation-Associated Protein 5 Dermatomyositis

So, Jacqueline

MDA5 and RP-ILD

Anti-melanoma differentiation-associated protein 5 (MDA5) positive dermatomyositis (DM) is associated with rapidly progressive interstitial lung disease (RP-ILD) and high mortality.

Objective: Identify predictors for mortality and RP-ILD. Hong Kong

101 patients from Hong Kong Myositis Registry

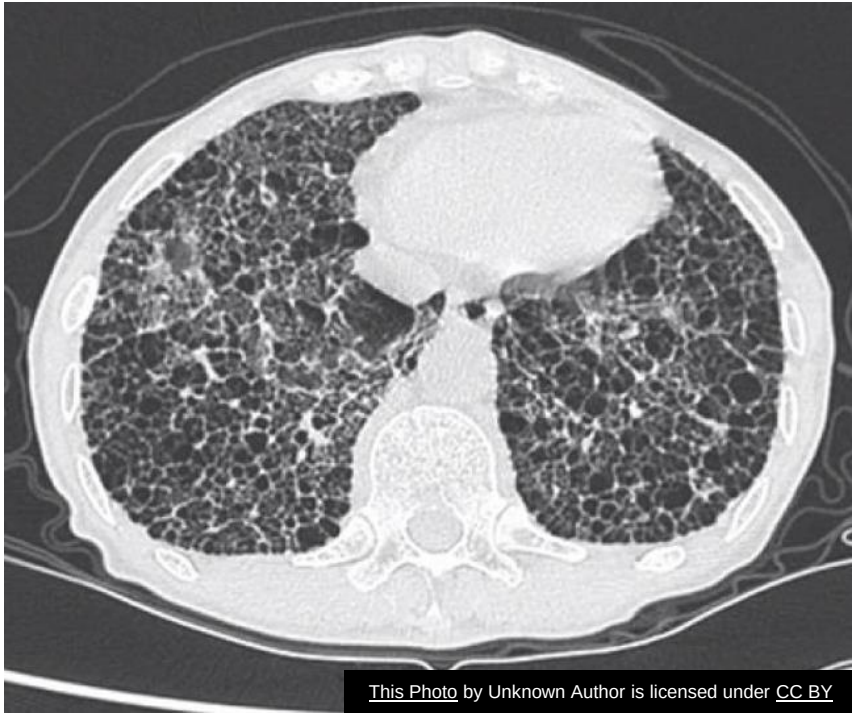

- 86% had ILD and 42% RP-ILD
- 38 patients died over 21 months
  - 31% within 3 months of Diagnosis

Predictors of mortality

- RP-ILD, smoking, ferritin level >2800pmol/L, and fever at diagnosis were independent predictors of mortality.
- Early rituximab use was associated with better survival

Predictors of RP-ILD

- Based on:
  - Neutrophil to Lymphocyte Ration >7.5
  - Age >50 years old
  - LDH >300IU/L

References

- Aoude M, Gupta L, Hmamouchi I*, et al*. OP0161 Treatment patterns of idiopathic inflammatory myopathies: Results from an international cohort of over 1,400 patients *Annals of the Rheumatic Diseases* 2022;**81:**105-106.
- Kastrati, K., Nakhost Lotfi, N., Tawfik, M., Gelpi, E., Hoeftberger, R., Kiener, H., Aletaha, D., Bonelli, M., & Radner, H. (2022). POS0911 diagnostic value and clinical relevance of muscle biopsy in patients with suspected myositis. *Annals of the Rheumatic Diseases*, *81*(Suppl 1). https://doi.org/10.1136/annrheumdis-2022-eular.4161
- Khadilkar, S. V., & Dhamne, M. C. (2020). What is new in idiopathic inflammatory myopathies: Mechanisms and therapies. *Annals of Indian Academy of Neurology*. https://doi.org/10.4103/aian.aian_400_19
- Liebowitz, J. (2021, December 14). *From strength to strength: Idiopathic inflammatory myopathy diagnosis & management*. The Rheumatologist. Retrieved June 30, 2022, from https://www.the-rheumatologist.org/article/from-strength-to-strength-idiopathic-inflammatory-myopathy-diagnosis-management/?singlepage=1&theme=print-friendly
- Lundberg, I. E., & Tjärnlund, A. (2017). Response to: '2017 EULAR/ACR classification criteria for adult and juvenile idiopathic inflammatory myopathies and their major subgroups: Little emphasis on autoantibodies, why?' by malaviya. *Annals of the Rheumatic Diseases*, *77*(11). https://doi.org/10.1136/annrheumdis-2017-212709
- Martino, S. D. (2019, January 20). *Inflammatory myositis*. Rheumatology Advisor. Retrieved June 30, 2022, from https://www.rheumatologyadvisor.com/home/decision-support-in-medicine/rheumatology/inflammatory-myositis/
- McLeish, E., Slater, N., Sooda, A., Wilson, A., Coudert, J. D., Lloyd, T. E., & Needham, M. (2022). Inclusion body myositis: The interplay between ageing, muscle degeneration and autoimmunity. *Best Practice & Research Clinical Rheumatology*, 101761. https://doi.org/10.1016/j.berh.2022.101761
- Schmidt, J. (2018). Current classification and management of inflammatory myopathies. *Journal of Neuromuscular Diseases*, *5*(2), 109–129. https://doi.org/10.3233/jnd-180308
- West, S. G., & Kolfenbach, J. (2020). *Rheumatology secrets*. Elsevier.